

Apoptosis of Cardiomyocytes in Myocarditis

(active myocarditis / apoptosis / TUNEL technique / active caspase 3 / p53 / bcl-2)

R. ZORC-PLESKOVIČ¹, A. ALIBEGOVIĆ², M. ZORC¹, A. MILUTINOVIĆ¹,
N. RADOVANOVIĆ³, D. PETROVIČ¹

¹Institute of Histology and Embryology, Medical Faculty, University Ljubljana, Ljubljana, Slovenia

²Institute for Forensic Medicine, Medical Faculty, University Ljubljana, Ljubljana, Slovenia

³Institute for Cardiovascular Diseases, Sremska Kamenica, Republic Serbia and Montenegro

Abstract. Apoptosis of cardiomyocytes has been reported to be involved in the pathogenesis of heart failure of different aetiologies. The purpose of this study is to assess the role and extent of apoptosis of cardiomyocytes in active myocarditis. Endomyocardial samples from the right ventricle of 22 patients with active myocarditis were compared with 25 traffic accident victims without a history of cardiovascular disease. Twenty-two patients fulfilled the histopathologic Dallas criteria for myocarditis. The TUNEL method and immunostaining for active caspase 3 were used for the detection of apoptosis. Immunohistochemical methods were used for the evaluation of regulators of apoptosis (p53, Bcl-2) and evaluation of interstitial cells (macrophages, T and B lymphocytes). Apoptosis of cardiomyocytes (TUNEL-positive and anti-caspase 3-positive cardiomyocytes), which was not p53-dependent, was present in 0.3 to 0.4 % (0.3 % by TUNEL method and 0.4 % by immunostaining for active caspase 3) of cardiomyocytes in active myocarditis, whereas only few apoptotic cardiomyocytes (0.0006 ± 0.002 % TUNEL-positive cardiomyocytes and 0.001 ± 0.002 % active caspase 3-positive cardiomyocytes) were found in the control group ($P = 0.001$). Apoptotic (TUNEL-positive and active caspase 3-positive) cardiomyocytes were found in small clusters. An increased expression of Bcl-2 was found in active myocarditis compared to the controls ($P < 0.01$), yet Bcl-2 failed to protect myocytes from apoptosis. We provide evidence of apoptosis of cardiomyocytes in active myocarditis, which may be involved in the development of heart failure.

Introduction

Myocarditis, an inflammatory process affecting the myocardium, may be caused by any bacterial, viral, rickettsial, mycotic, or parasitic organism (Woodruff, 1980; Billingham, 1987; Braunwald, 1997). In Europe most

cases of acute myocarditis are caused by viruses (Billingham, 1987). Viral myocarditis is associated with elevated levels of pro-inflammatory cytokines, interleukin-1 β , tumour necrosis factor α , and soluble Fas and Fas ligand (Freeman et al., 1998; Fuse et al., 2000). Apoptosis of cardiomyocytes has been demonstrated in some animal models of viral myocarditis, whereas the reports of cardiomyocyte apoptosis in myocarditis in human are not consistent (Kawano et al., 1994; Alter et al., 2001; Kyto et al., 2004). Several reports suggest that immunostaining for active caspase-3 is a more sensitive and reliable marker of apoptosis than the terminal transferase-mediated DNA nick-end labelling (TUNEL) method (Enari et al., 1998; Gown and Willingham, 2002).

The *p53* gene and the *bcl-2* proto-oncogene are involved in the regulation of apoptosis: the p53 protein promotes cell death, whereas the Bcl-2 protein is implicated in cell survival (Miyashita et al., 1994; Reed, 1994). Moreover, it seems that in heart failure the Bcl-2 is overexpressed (Olivetti et al., 1997).

Previously we have reported apoptosis of cardiomyocytes in dilated cardiomyopathy (DCM) and that apoptosis, Bcl-2 expression and proliferation activity of myocytes, myofibril volume fraction, and volume density of interstitial tissue might be useful in predicting the prognosis (progressive versus non-progressive form) of patients with heart failure due to DCM (Petrovič et al., 2000; Zorc et al., 2003).

The aim of this study was to evaluate the role and extent of apoptosis of cardiomyocytes in active myocarditis.

Material and Methods

In 110 patients with an unexplained congestive heart failure, endomyocardial biopsies from the right ventricle were performed at the University Medical Centre, Ljubljana, Slovenia, and at the Clinic for Cardiovascular Diseases, Sremska Kamenica, Republic of Serbia and Montenegro. All patients were New York Heart Association class III or IV (Braunwald, 1997). Endomyocardial biopsies were performed for diagnostic purposes (Billingham, 1987; Braunwald, 1997; Kyto et al., 2005). The initial investigation included the chest x-ray examination,

Received March 31, 2006. Accepted April 12, 2006.

Corresponding author: Daniel Petrovič, Institute of Histology and Embryology, Medical Faculty, University Ljubljana, Korytkova 2, 1105 Ljubljana, Slovenia. Phone: (+386) 1 543 7367; Fax: +386 1 543 7361; e-mail: daniel.petrovic@mf.uni-lj.si

Abbreviations: PBS – phosphate-buffered saline, TUNEL – terminal transferase-mediated DNA nick-end labelling.

electrocardiography, echocardiography, and cardiac catheterization with coronary arteriography and ventriculography. The results of these investigations were consistent with the diagnosis of dilated cardiomyopathy. The Dallas criteria were used for the histopathological definition and classification of myocarditis (Billingham, 1987). In a few cases the diagnosis was additionally confirmed at the Institute for Forensic Medicine in Medical Faculty Ljubljana. Active myocarditis was found in 22 (20 %) patients. Endomyocardial specimens of the right ventricle of 25 traffic accident victims without a history of cardiovascular disease were used as the control group. In patients with active myocarditis the mean age was 39.4 (SD = 12.3) years, and in the control group of patients it was 38.5 (SD = 14.8) years.

Tissue sampling

In patients and controls the tissues were taken from the apical septal aspect of the right ventricle using the biptome. The tissue samples were immediately put into 10 % buffered formalin, fixed for less than 24 hours and embedded in paraffin.

Apoptosis was detected with the TUNEL method (ONCOR Apo Tag plus Peroxidase Kit, Gaithersburg, MD). Four- μ m paraffin sections were deparaffinized and endogenous peroxidase was blocked by immersing the sections in phosphate-buffered saline (PBS) containing 0.5 % H_2O_2 for 15 min. The nuclei of tissue sections were stripped from proteins by incubation with proteinase K (concentration: 20 μ g/ml, incubation 15 min; Sigma, Deisenhofen, Germany). The sections were incubated with a mixture of terminal deoxynucleotidyl transferase (TdT) and reaction buffer containing digoxigenin-labelled dUTP. Haematoxylin staining followed the incubation with anti-digoxigenin antibody conjugated with peroxidase. Rat thymus sections were used as positive controls.

Immunohistochemistry

Four- μ m paraffin sections were deparaffinized. For all immunohistochemical analyses the sections were heated in a microwave oven (15 min for Bcl-2, CD3, CD79 α , CD68, and 10 min for p53). The sections were washed with PBS. Endogenous peroxidase was blocked with 3 % H_2O_2 in PBS for 30 min. To block non-specific binding sites the slides were covered with 2 % bovine serum albumin in PBS. After washing in PBS the primary antibodies were applied: Bcl-2 monoclonal antibody (DAKO, A/S, Glostrup, Denmark; dilution 1 : 50); p53 monoclonal antibody (DAKO; dilution 1:100); for apoptotic cells – anti-active caspase 3 mouse monoclonal antibody (Cell Signaling Technology, Danvers, MA; dilution 1 : 100); for T cells – CD3 rabbit anti-human monoclonal antibodies (DAKO; dilution 1 : 40); for B cells – CD79 α anti-human monoclonal antibodies (DAKO; dilution 1 : 40); and for macrophages – CD68 mouse anti-human monoclonal antibodies (DAKO;

dilution 1 : 40). After washing in PBS, the primary antibodies were detected by incubation with biotinylated goat antibodies for 30 min. After washing in PBS, streptavidin-biotin complex/horseradish peroxidase was applied for 30 min at room temperature (ABC, DAKO). Diaminobenzidine was used as chromogen substrate for all immunohistochemical analyses. Specificity test, performed by omission of the primary serum, produced negative results for all the antibodies used. Lymph nodes were used as positive controls for Bcl-2, and p53-positive breast carcinoma for p53.

Each cardiomyocyte (nucleus or cytoplasm) stained immunohistochemically with different antibodies (Bcl-2, p53, caspase 3) was classified as labelled or not labelled. In each patient 200 to 300 cardiomyocytes were evaluated.

Statistics

The clinical characteristics (age) and morphometrical data (percentage of apoptotic cardiomyocytes, percentage of Bcl-2-positive cardiomyocytes) of the two groups were compared by Student's t-test and expressed as mean \pm standard deviation (SD). The value of $P < 0.01$ was considered significant. The χ^2 test was used to compare discrete variables.

Results

We found 0.5 % (SD = 0.3 %) of TUNEL-positive cardiomyocytes (Fig. 1) in 16 patients with active myocarditis (73 % of patients with active myocarditis), and none in the remaining six patients with active myocarditis (27 % of patients with active myocarditis).

Only three (0.0006 \pm 0.002 %) TUNEL-positive cardiomyocytes were found in the control group. In patients with active myocarditis, 0.3 % (SD = 0.2 %) of myocyte nuclei were TUNEL-positive. Additionally, we found 0.6 % (SD = 0.3 %) of active caspase 3-positive cardiomyocytes (Fig. 2) in 17 patients with active myocarditis (77 % of patients with active myocarditis), and none in the remaining five patients with active myocarditis (23 % of patients with active myocarditis). Only five (0.001 \pm 0.002 %) active caspase 3-positive cardiomyocytes were found in the control group. In patients with active myocarditis, 0.4 % (SD = 0.2 %) of myocytes were active caspase 3-positive. Apoptotic (TUNEL-positive and active caspase 3-positive) myocytes were observed in small clusters. In one patient with active myocarditis, mismatch between TUNEL assay and active caspase 3 immunostaining was observed, i.e. cardiomyocytes were TUNEL-negative and active caspase 3-positive.

In the active myocarditis group, interstitial cells were in a group of infiltrates (Fig. 3). They were classified as lymphocytes T in 42 % (SD = 21 %), macrophages in 34 % (SD = 16 %) and lymphocytes B in 20 % (SD = 13 %).

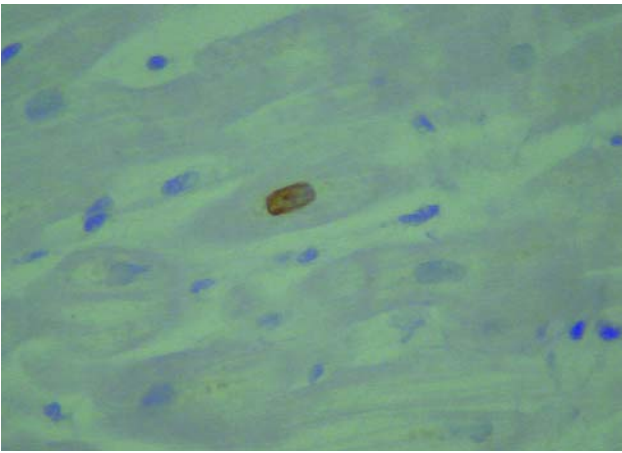


Fig. 1. Two TUNEL-positive cardiomyocytes in a patient with myocarditis (x 40).

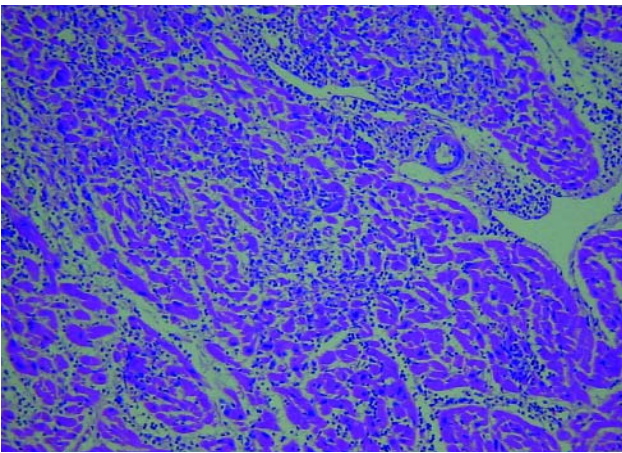


Fig. 3. Mononuclear infiltrates in myocarditis (x 10).

Apoptosis (TUNEL-positive and active caspase 3-positive cells) was demonstrated in 5 % of interstitial cells.

The percentage of cardiomyocytes labelled with Bcl-2 (Fig. 4) was higher in diseased hearts (myocarditis) than in control hearts ($30 \pm 12\%$ vs. $12 \pm 7\%$, $P < 0.01$). The cardiomyocyte nuclei of patients with myocarditis and controls were not labelled with p53, whereas p53-positive breast carcinoma were.

Discussion

We found evidence of apoptosis of cardiomyocytes in heart biopsies of the patients with active myocarditis. Cardiomyocyte apoptosis was detected in two thirds of the patients with myocarditis. Apoptotic cardiomyocytes were observed in small clusters. A high percentage of apoptotic cardiomyocytes have been reported by Alter and co-workers (2001) and Kyto and co-workers (2004). Alter and co-workers (2001) demonstrated 6.15 % of TUNEL-positive myocytes in severe active myocarditis, and Kyto and co-workers (2004) demonstrated 2.0 % of apoptotic (TUNEL-positive and active caspase 3-positive) myocytes in fatal myocarditis. Kawano and co-workers (1994), on the other hand, failed to demonstrate evidence of apoptosis in heart

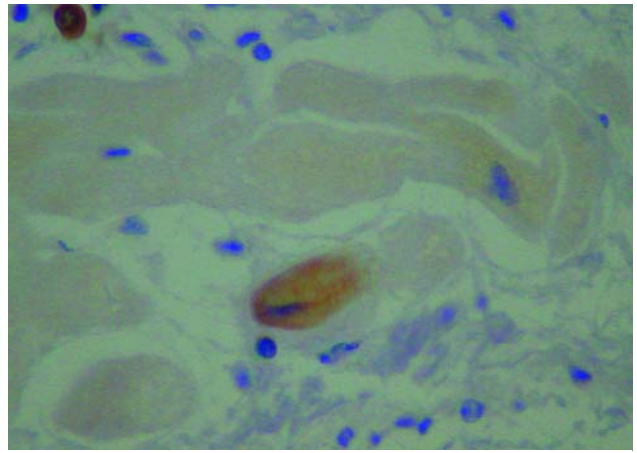


Fig. 2. Immunohistochemical staining for active caspase 3-positive cardiomyocyte in a patient with myocarditis: positive reaction in one lymphocyte (one arrow) and one cardiomyocyte (two arrows) in (x 40).

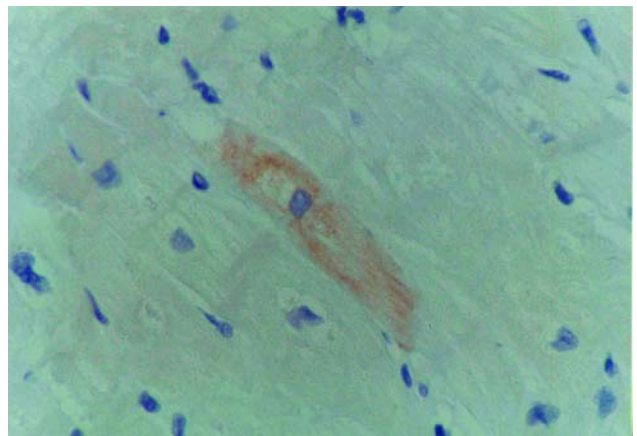


Fig. 4. Immunohistochemical staining for Bcl-2 in a patient with myocarditis: positive reaction in one cardiomyocyte (x 40).

biopsies of three patients with acute myocarditis. The differences in the extent of apoptotic cardiomyocytes in myocarditis between these reports might be due to several reasons: differences in timing of endomyocardial procedure, different severity of the disease, different methods used for the detection of apoptosis. Apoptosis of cardiomyocytes has been reported previously in animal models of viral myocarditis; however, different variants of viruses have induced different pathological mechanisms, and moreover, different strains of mice were affected differently (Fowles and Mason, 1984). Colston and co-workers (1998) have reported extremely rare myocardial TUNEL-positive cells in acute phase of experimental coxsackievirus myocarditis, and have concluded that apoptosis of myocytes contributes minimally to the myocardial degeneration observed during the acute phase of experimental coxsackievirus myocarditis (Colston et al., 1998). The absence of apoptosis in six (27 %) of cases with active myocarditis in our study may be due to several reasons: focal nature of the disease, transient nature of the apoptosis of myocytes resulting from its rapid induction and the

rapid clearance of apoptotic debris, and timing of endomyocardial biopsy, i.e. endomyocardial biopsy was performed at least a few weeks after the initial insult, in the immunological phase of myocarditis (Savill et al., 1993).

In one patient with active myocarditis, mismatch between TUNEL assay and active caspase 3 immunostaining was observed. This mismatch is most probably due to early activation of caspase 3 in the process of apoptosis, leading finally to DNA fragmentation (Enari et al., 1998). Very early in the process of apoptosis, cardiomyocytes may be active caspase 3-positive, and at the same time TUNEL-negative, since DNA fragmentation is not yet present.

Beside apoptosis of cardiomyocytes in active myocarditis, a number of interstitial cells (predominantly inflammatory cells) were undergoing apoptosis. We speculate that apoptosis of interstitial cells may be the mode of disappearance of interstitial cells in myocarditis. Strand and co-workers (1996) have reported that in tumours, infiltrating immune cells are destroyed by the induction of apoptosis through the expression of Fas ligand on the tumour cell that binds Fas on lymphocytes.

Apoptosis of cardiomyocytes was not p53-dependent; therefore other mechanisms might be responsible for the activation of programmed cell death. The percentage of cardiomyocytes that were labelled with Bcl-2 was higher in diseased hearts (active myocarditis) than in control hearts. Interestingly, Colston and co-workers (1998) have demonstrated an increased expression of cytoplasmic Bcl-2 in cardiomyocytes in coxsackievirus B3-infected mice, followed by a return to the normal level within several weeks. We speculate that over-expression of Bcl-2 in the hearts of patients with active myocarditis compared to the control group might be an attempt to maintain the cell survival in myocarditis.

We provide evidence of apoptosis of cardiomyocytes in active myocarditis, which may be involved in the development of heart failure.

Acknowledgements

The authors thank Ms. Mojca Pirc, BA. for revising the English text.

References

- Alter, P., Jobmann, M., Meye, E., Punkuweit, S., Maisch, B. (2001) Apoptosis in myocarditis and dilated cardiomyopathy: does enterovirus genome persistence protect from apoptosis? An endomyocardial biopsy study. *Cardiovasc. Pathol.* **10**, 229-234.
- Billingham, M. (1987) Acute myocarditis: a diagnostic dilemma. *Br. Heart J.* **58**, 6-8.
- Braunwald, E. (1997) Heart failure. In: *Harrison's Principles of Internal Medicine*, 14th edition, eds. Isselbacher K. J., Braunwald E., Wilson J. D., Martin J. B., Fauci A. S., Kasper D. L., pp. 1105-1135, McGraw-Hill, New York, St. Louis, London.
- Colston, J. T., Chandrasekar, B., Freeman, G. L. (1998) Expression of apoptosis related proteins in experimental viral myocarditis. *Cardiovasc. Res.* **38**, 158-168.
- Enari, M., Sakahira, H., Yokoyama, H., Okawa, K., Iwamatsu, A., Nagata, S. (1998) A caspase-activated DNase that degrades DNA during apoptosis, and its inhibitor ICAD. *Nature* **391**, 43-50.
- Fowles, R. E., Mason, J. W. (1984) Role of cardiac biopsy in the diagnosis and management of cardiac disease. *Prog. Cardiovasc. Dis.* **27**, 153-172.
- Freeman, G. L., Colston, J. T., Zabalgoitia, M., Chandrasekar, B. (1998) Contractile depression and expression of proinflammatory cytokines and inducible nitric oxide synthase in viral myocarditis. *Am. J. Physiol.* **274**, H249-H258.
- Fuse, K., Kodama, M., Okura, Y. (2000) Predictors of disease course in patients with acute myocarditis. *Circulation* **102**, 2829-2835.
- Gown, A. M., Willingham, MC. (2002) Improved detection of apoptotic cells in archival paraffin sections: immunohistochemistry using antibodies to cleaved caspase 3. *J. Histochem. Cytochem.* **50**, 449-454.
- Kawano, H., Okada, R., Kawano, Y., Sueyoshi, N., Shirai, T. (1994) Apoptosis in acute and chronic myocarditis. *Jpn. Heart J.* **35**, 745-750.
- Kyto, V., Saraste, A., Saukko, P., Henn, V., Pulkki, K., Vuorinen, T., Voipio-Pulkki, L. M. (2004) Apoptotic cardiomyocyte death in fatal myocarditis. *Am. J. Cardiol.* **94**, 746-750.
- Kyto, V., Saukko, P., Lignitz, E., Schwesinger, G., Henn, V., Saraste, A., Voipio-Pulkki, L. M. (2005) Diagnosis and presentation of fatal myocarditis. *Hum. Pathol.* **36**, 1003-1007.
- Miyashita, T., Harigai, M., Hanada, M., Reed, J. C. (1994) Identification of a p53-dependent negative response element in the Bcl-2 gene. *Cancer Res.* **54**, 3131-3135.
- Olivetti, G., Abbi, R., Quaini, F., Kajstura, J., Cheng, W., Nitahara, J.A., Quaini, E., Di Loreto, C., Beltrami, C. A., Krajewski, S., Reed, J. C., Anversa, P. (1997) Apoptosis in the failing human heart. *N. Engl. J. Med.* **336**, 1131-1141.
- Petrovič, D., Zorc-Pleskovič, R., Zorc, M. (2000) Apoptosis and proliferation of myocytes in heart failure of different etiologies. *Cardiovasc. Pathol.* **9**, 149-152.
- Reed, J. C. (1994) Bcl-2 and the regulation of programmed cell death. *J. Cell Biol.* **124**, 1-6.
- Savill, J., Fodok, V., Henson, P., Haslett, C. (1993) Phagocytic recognition of cells undergoing apoptosis. *Immunol. Today* **14**, 131-136.
- Strand, S., Hofmann, W. J., Hug, H., Muller, M., Otto, G., Strand, D., Mariani, S. M., Stremmel, W., Krammer, P. H., Galle, P. R. (1996) Lymphocyte apoptosis induced by CD95 (apoA1/Fas) ligand-expressing tumor cells – a mechanism of immune evasion? *Nat. Med.* **2**, 1361-1366.
- Woodruff, J. F. (1980) Viral myocarditis: a review. *Am. J. Pathol.* **101**, 425-466.
- Zorc, M., Vraspir-Porenta, O., Zorc-Pleskovic, R., Radovanovic, N., Petrovic, D. (2003) Apoptosis of myocytes and proliferation markers as prognostic factors in end-stage dilated cardiomyopathy. *Cardiovasc. Pathol.* **12**, 36-39.