

Original Article

Mycophenolate Mofetil and Cyclophosphamide Treatments Suppress Inflammation Intensity in an Experimental Model of Autoimmune Uveitis

(experimental autoimmune uveitis / autoimmunity / retinal antigen / uveitis / uveoretinitis / mouse / mycophenolate mofetil / cyclophosphamide / golimumab)

A. KLÍMOVÁ¹, P. SEIDLER ŠTANGOVÁ¹, J. HEISSIGEROVÁ¹, P. SVOZÍLKOVÁ¹, T. KUČERA²

¹Department of Ophthalmology, First Faculty of Medicine, Charles University in Prague and General University Hospital in Prague, Czech Republic

²Institute of Histology and Embryology, First Faculty of Medicine, Charles University in Prague, Czech Republic

Abstract. In human, autoimmune uveitis is a leading cause of visual disability and ranks with diabetic retinopathy as a major source of blind registrations in developed countries. Since most cases of non-infectious uveitis are considered to be autoimmune or at least immune-mediated, the management of such patients has rested on appropriate immunosuppression. Some patients, however, despite maximal immunotherapy, fail to respond or are seriously intolerant of the drug therapies. Since its establishment 20 years ago, the model of experimental autoimmune uveoretinitis has served as a useful template for novel therapeutic approaches. The aim of our study was to compare the efficacy of mycophenolate mofetil and cyclophosphamide and golimumab treatment in the mouse model of experimental autoimmune uveitis. The intensity of intraocular inflammation was evaluated histologically in the treatment and control

groups. Experimental autoimmune uveitis has been induced in mouse strain C57BL/6 by subcutaneous application of interphotoreceptor retinoid binding protein in complete Freund's adjuvant and pertussis toxin. The treatment was commenced on the day of uveitis induction. Cyclophosphamide was applied intraperitoneally in a single dose (100 mg/kg), mycophenolate mofetil intraperitoneally daily (30 mg/kg or 50 mg/kg), golimumab subcutaneously weekly (70 mg/kg). Sham intraperitoneal injection of a placebo (aqua pro injectione) and untreated mice with experimental autoimmune uveitis served as controls. The results show statistically significant suppression of experimental uveitis both with mycophenolate mofetil and with cyclophosphamide, and thus support its use in human medicine.

Introduction

Uveitis is an intraocular inflammation, which is one of the major causes of blindness in developed countries in patients of working age. It has been estimated that uveitis causes 10 % of the cases of blindness in these countries (Suttorp-Schulten and Rothova, 1996; Durrani et al., 2004). Since most cases of non-infectious uveitis are considered to be autoimmune or at least immune-mediated, the management of such patients has rested on appropriate immunosuppression. Some patients, however, despite maximal immunotherapy, fail to respond or are seriously intolerant of the drug therapies. Therefore, further research is needed to find optimal treatment for these patients.

The heterogeneity of the disease with a wide spectrum of clinical presentations is the major impediment to extensive human studies. Because of that, animal models of autoimmune uveitis have been developed to allow more detailed studies of this disease and help to

Received March 16, 2014. Accepted May 30, 2014.

This study was supported by Grant GA UK No. 910/154250045-295211 from the First Faculty of Medicine, Charles University in Prague, Czech Republic, by research project from the Ministry of Health of the Czech Republic IGA MZ NT/14017-3/2013, by Grant SVV UK 266505/2013 and research programme of Charles University in Prague – PRVOUK P25/LF1/2.

Corresponding author: Aneta Klímová, Department of Ophthalmology, First Faculty of Medicine, Charles University in Prague and General University Hospital in Prague, U nemocnice 2, 128 08 Prague 2, Czech Republic. e-mail: aneta.klimova@volny.cz

Abbreviations: CFA – complete Freund's adjuvant, CPA – cyclophosphamide, DMSO – dimethyl sulphoxide, EAU – experimental autoimmune uveitis, IRBP – interphotoreceptor retinoid binding protein, MMF – mycophenolate mofetil, PBS – phosphate-buffered saline, TNF – tumour necrosis factor.

seek new immunological therapeutic strategies (Caspi et al., 1990a; Forrester et al., 1990, 1992). At present, the most widely used is the model of experimental autoimmune uveitis (EAU) in mice, where the uveitis is induced by subcutaneous application of interphotoreceptor retinoid binding protein (IRBP) in complete Freund's adjuvant (CFA) (Caspi et al., 1988). IRBP works as a retinal autoantigen (Avichezer et al., 2000; Broderick et al., 2002). The mouse strain C57BL/6, in which application of IRBP 1-20 causes a chronic mild inflammation, mainly involving the posterior segment of the eye (Xu et al., 2008), imitates posterior uveitis in humans probably most closely.

In the treatment of uveitis, cyclophosphamide (CPA) is probably the most powerful immunosuppressant used (Mochizuki et al., 1985; Suzuki et al., 1989). Its effect has been proved in rodent models of EAU (Caspi et al., 1990b) and in human medicine (Suelves et al., 2013).

The role of mycophenolate mofetil (MMF) remains unconvincing. MMF has been reported to be effective (Siepmann et al., 2006; Teoh et al., 2008; Doycheva et al., 2011) in the treatment of human autoimmune uveitis when compared to other immunosuppressants. Its effects in the treatment of severe uveitis are, however, rather disappointing when compared to its successful use in treatment of other ocular immunological diseases, such as ocular cicatricial pemphigoid and corneal transplantation (Zierhut et al., 2005). In an experimental model of EAU in Lewis rats (Chanaud et al., 1995; Dick et al., 1998), MMF was proved successful. As our model is probably the best to be compared to human autoimmune uveitis and as this drug has not been tested in mice with EAU, in this study, the efficacy of MMF has been compared with well-established treatment with CPA and with humanized monoclonal antibody golimumab. We have shown significant suppression of ocular inflammation with MMF and with CPA.

Material and Methods

Animals

The experimental use of animals was approved by The Commission for Animal Welfare of the First Faculty of Medicine of Charles University in Prague, Czech Republic, and the Ministry of Education, Youth and Sports according to animal protection laws. All the procedures were approved by the animal experimentation review committee.

Inbred female mice of the C57BL/6 strain 5 to 8 weeks old were obtained from the animal facility of the Centre of Experimental Biomodels (First Faculty of Medicine, Charles University in Prague, Czech Republic).

Induction of experimental autoimmune uveitis

The application of IRBP was conducted according to a standard protocol (Avichezer et al., 2000; Broderick et al., 2002). In brief: subcutaneous injection of 500 µg of IRBP 1-20 (interphotoreceptor retinoid binding protein,

also called retinol-binding protein 3 precursor fragment [Homo sapiens] H2N-GPHTLFPQSLVLDMAKVLLD-OH, New England Peptide, Gardner, MA) was applied. To dissolve the IRBP peptide, DMSO (dimethyl sulphoxide) (Sigma-Aldrich, St. Louis, MO) was used. IRBP was emulsified in ratio 1 : 1 with CFA (Difco Laboratories, Detroit, MI). The reactivity of the immune system was enhanced by intraperitoneal application of 1.2 µg pertussis toxin (List Biologicals, Campbell, CA) dissolved in PBS.

Study groups

In this study, four treatment groups and three control groups were used. In the treatment groups, two groups of mice were treated with MMF (Cellcept 1 g/5 ml, Roche, Welwyn Garden City, Great Britain). MMF was injected intraperitoneally daily in a dose of 30 mg/kg (32 eyes) and in a dose of 50 mg/kg (13 eyes). The following group of mice was treated with CPA (Endoxan 1 g, Baxter, Halle, Germany). CPA was injected intraperitoneally in a single dose of 100 mg/kg (29 eyes). The last treatment group was treated with golimumab (Simponi 50 mg, Janssen Biologics, Leiden, Netherlands). Golimumab was injected subcutaneously weekly in a dose of 70 mg/kg (16 eyes). We had three control groups: group without EAU induction (8 eyes), group with EAU without treatment (88 eyes) and group with EAU with sham treatment (aqua pro injection applied intraperitoneally; 14 eyes). The odd count of eyes in some groups was caused by a congenital anomaly, microphthalmos, which occurs relatively often in inbred animals.

Specimen preparation and histological processing

The mice were sacrificed following the ethical rules given by the law (§17) in the Czech Republic by cervical spine manipulation. The eyes were enucleated promptly post mortem on day 35 after the induction of EAU. Enucleation in mice was performed by dissecting the globe carefully from periocular tissue. The eyeballs were placed in gel medium (Tissue-Tek® O.C.T. Compound™, Sakura Finetek USA, Inc., Torrance, CA) and frozen in 2-methylbutane (Sigma-Aldrich) in nitrogen atmosphere. The samples, frozen to -70 °C, were then cut by a microtome Leica CM 1850 (Leica Microsystems Nussloch GmbH, Nussloch, Germany) to 7 µm thick slices. The sections were always cut from both eye peripheries and also through the optic nerve. The samples were stained with haematoxylin and eosin according to a standard protocol. The samples were taken from both eyes, since the intensity of inflammation may be asymmetric.

Clinical examination of uveitis

The clinical examination in living animals (bio-microscopy) was performed using a special endoscopic imaging system. The mice were examined in intraperitoneal general anaesthesia with ketamine 80 mg/kg

(Narkamon 50 mg/ml, Bioveta, Nitra, Slovakia) and xy-lazine 5 mg/kg (Rometa 20 mg/ml, Bioveta, Slovakia). The pupils were dilated by tropicamide (Unitropic 1% oph. gtt., Unimed Pharma, Bratislava, Slovakia) and phenylephrine hydrochloride (Neosynephrin-Pos 10 %, Ursahpharm, Říčany, Czech Republic) and anaesthetized with oxybuprocaine hydrochloride (Benoxi 0.4% Unimed Pharma, Unimed Bohemia, Czech Republic). An otoscope with external light source was connected to a camera (Paques et al., 2007). The otoscope was placed on the cornea covered with eye gel.

Statistical analysis

Data were analysed using GraphPad Prism Version 6.04 for Windows (GraphPad Software, San Diego, CA, www.graphpad.com). Kruskal-Wallis and Mann-Whitney non-parametric tests were used to assess differences between the data groups. The P value of < 0.05 was con-

sidered significant. Variation among column medians was significantly greater than expected by chance.

Results

The evaluation of the inflammation intensity, and hence the effect of EAU treatment, was evaluated by a histological scoring system. The histological specimens of eye sections stained with haematoxylin and eosin were evaluated microscopically by two experienced eye specialists. To assess the intensity of retinal inflammation, we used the histopathological grading score from 0 to 4, see Table 1 (Caspi et al., 1988; Dick et al., 1994; Thureau et al., 1997).

Evident histological signs of posterior uveitis are retinal folds, granulomas in the retina, often located in the corpus ciliare, then vasculitis, vitritis, retinal neovascularization and photoreceptor loss (Figs. 1–6). The retina

Fig. 1-7. Representative haematoxylin and eosin histological images of mouse retinal sections showing EAU features on day 35 after immunization. Scale bars are shown in the images.

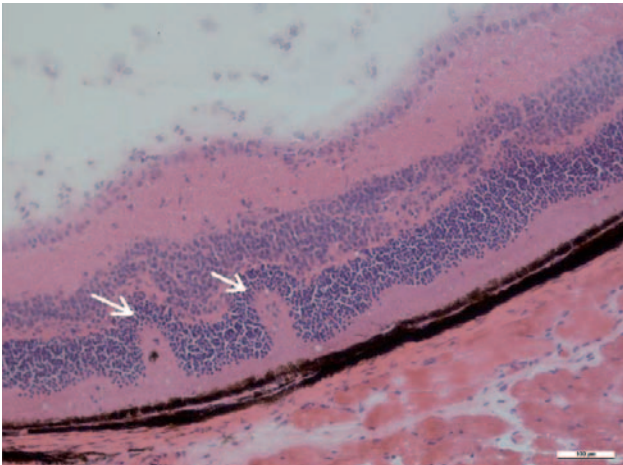


Fig. 1. Typical histological features of EAU are retinal folds (arrows), retinal layers are irregular in thickness and cellularity, inflammatory cells are present in the corpus vitreum.

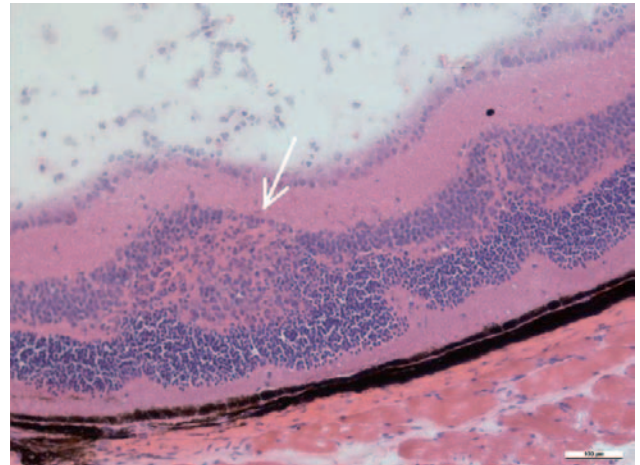


Fig. 2. Large retinal granuloma (arrow) is formed between the cellular layers in the retina, formation of retinal folds is apparent in the same location, inflammatory cells are present in the corpus vitreum.

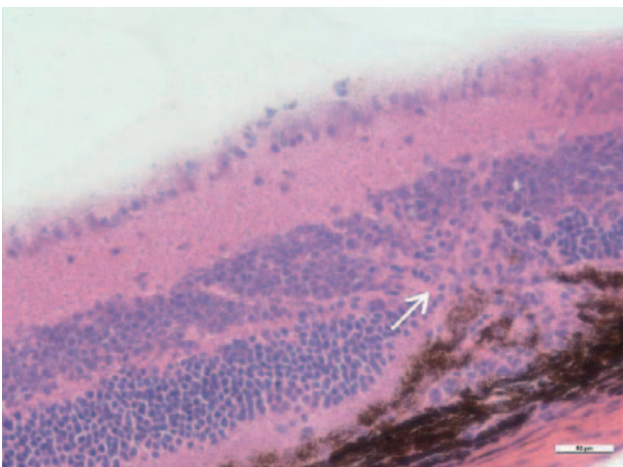


Fig. 5. Chorioretinitis in EAU is accompanied by new vessel formation; subretinal neovascularization (arrow) bursts from choroidal vessels through the retinal pigment epithelium and the Bruch's membrane into the retina.

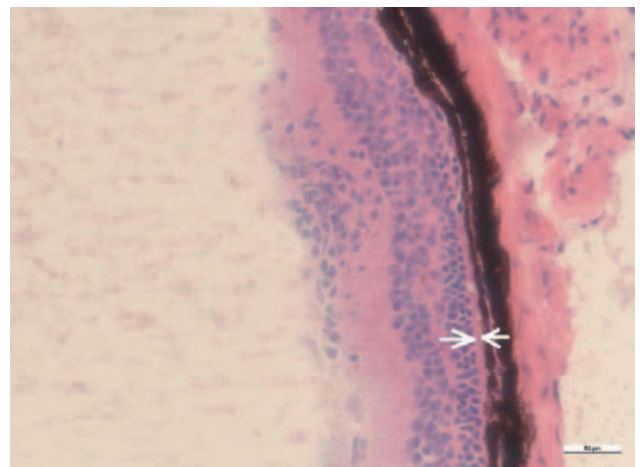


Fig. 6. The outer retinal layer with rods and cones is reduced by the inflammation, the significant photoreceptor loss (arrows) is a histopathological sign of advanced EAU.

Table 1. EAU scoring system

| Grade | Description |
|-------|--|
| 0 | No signs of inflammation |
| 0.5 | Small cellular infiltrate in ciliary body or sub-retinal space, non-granulomatous infiltrates in retina/choroid |
| 1 | Occasionally small retinal folds, single granulomatous infiltrate per section, mild perivasculitis, mild vitritis |
| 2 | Mild/moderate photoreceptor loss, 2 moderate-sized retinal folds per section, 1-2 granulomatous infiltrates per section, vasculitis < 10 % vessels, mild to moderate vitritis, cells in anterior chamber |
| 3 | Severe photoreceptor loss, 3 or more moderate or large retinal folds, more than 3 granulomatous infiltrates, vasculitis 10–50 % vessels, marked vitritis |
| 4 | Severe photoreceptor loss, extensive retinal folding or detachment, subretinal exudate, more than 3 large granulomas, vasculitis > 50 % vessels, severe vitritis |

in a healthy mouse has clearly defined layers without any irregularities (Fig. 7).

The clinical evaluation of inflammation features of EAU by ophthalmoscopic examination of the retina *in vivo* is not a main focus of this article. The clinical signs

of intraocular inflammation are seen clearly on the photographs of the retina, taken by the endoscopic fundus imaging system. The clinical grading system of EAU was described thoroughly by Xu et. al. (2008). The signs seen on our fundus image are focal infiltrations along the reti-

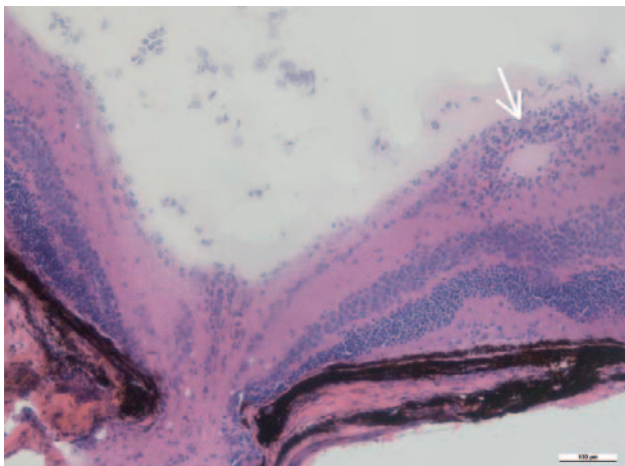


Fig. 3. Vasculitis with thick infiltration of the retinal vessel wall (arrow) is located close to the optic nerve.

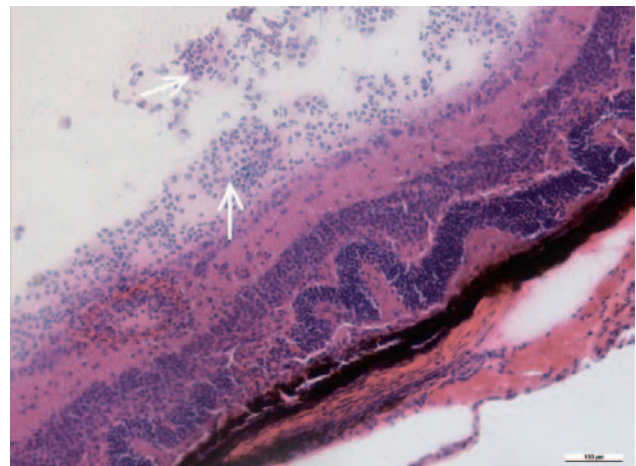


Fig. 4. Histological image showing grade 4 EAU: severe vitritis is represented by a collection of inflammatory cells in the corpus vitreum (arrows), severe vasculitis with wall infiltration and several retinal folds.

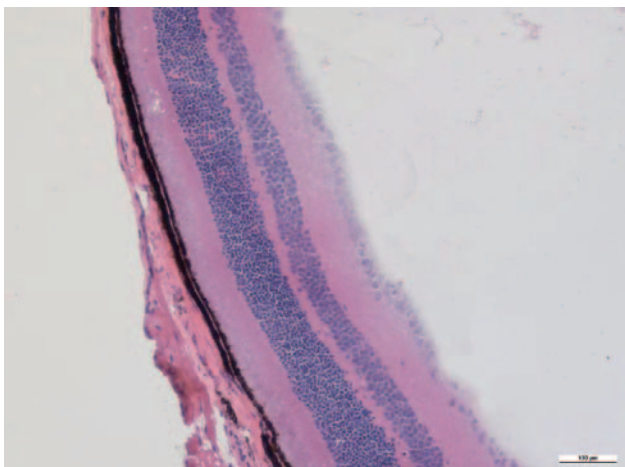


Fig. 7. Histological section of healthy retina with regular retinal layers.

Fig. 8-9. Mouse retinal images showing the posterior pole of the fundus were taken using the endoscopic fundus imaging system.

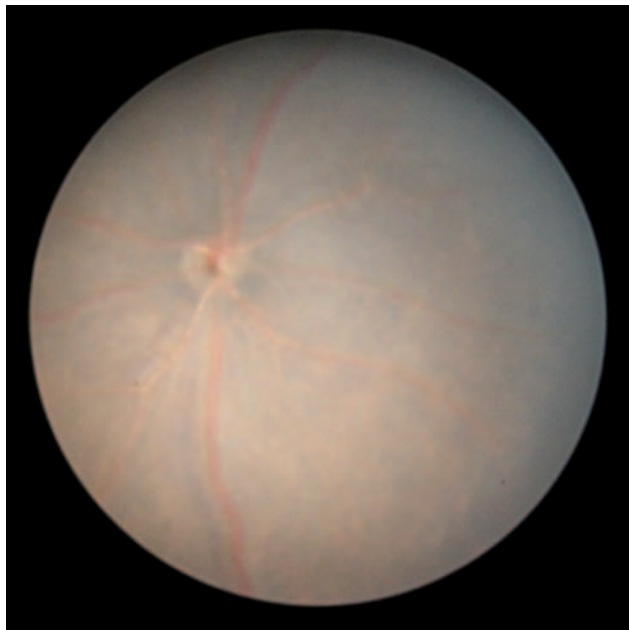

Fig. 8. Normal mouse fundus image taken from an 8-week-old healthy control mouse. The image was taken during general anaesthesia after pupil dilatation using mydriatic drops.

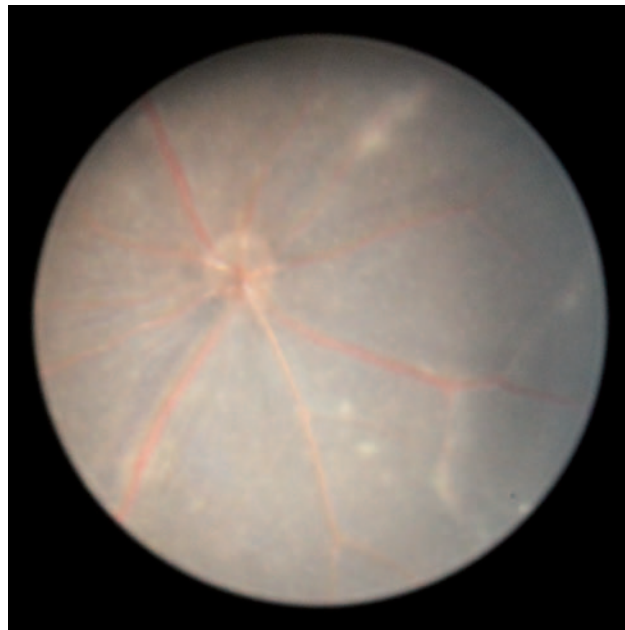


Fig. 9. Retinal changes during EAU in a C57BL/6 mouse are shown in a fundus image taken from day 28 post immunization. Several linear lesions and a small lesion show mild inflammation.

nal vessels (vasculitis), round lesions of various sizes (choroiditis) and oedema of the optic nerve (Figs. 8 and 9).

The aim of our study was to assess the efficacy of MMF compared to well-established treatment with CPA and humanized monoclonal antibody golimumab. The results of our study are outlined in a graph (Fig. 10). The treatment with CPA represented a positive control and it reflects the fact that all eyes in this group (29 eyes) were completely treated. This result was very highly significant ($P < 0.0001$) when compared to all control groups, including the sham treated group.

Treatment with antimetabolite drug MMF was applied in two dosage regimens. The lower dose of MMF (30 mg/kg; 32 eyes) resulted in statistically significant suppression of inflammation ($P < 0.05$) when compared to all control groups, including the sham treated group. The higher dose of MMF, 50 mg/kg (13 eyes), suppressed the EAU intensity; however, the results did not reach statistical significance. We presume that the higher dose did not prove statistical significance due to the high number of eyes in the control group. MMF in both doses was well tolerated by mice; as a side effect, we observed only a local fur loss in most of the animals. Our study thus supports the use of MMF in autoimmune posterior uveitis in humans.

Golimumab treatment has not shown any effect in rodent models due to its human origin and we used golimumab only as a negative control. From histological evaluation it is obvious that golimumab induced rather more severe inflammation; the results, however, were not statistically significant.

Discussion

Uveitis is a sight-threatening condition which in humans is difficult to treat. The immunosuppressants and biological therapy applied according to the present knowledge do not always prove effective in patients with autoimmune uveitis. As a vision-saving regimen, there are several treatment options.

CPA is a cytotoxic alkylating agent, which inhibits DNA replication. CPA is a strong cytostatic and immunosuppressive drug, it eliminates proliferating lymphoid cells, but also some quiescent cells. In humans, the suppressive effect of CPA has been known for a long time. CPA is used in patients in the case of failure of other immunomodulatory regimens or as a first line therapy in fulminant or life-threatening diseases (Khan et al., 2013; Suelves et al., 2013). Suzuki et al. (1989) observed in rats that application of CPA on the day before immunization markedly suppressed EAU development. Our study on EAU in mice confirmed an absolute anti-inflammatory effect of CPA, which was applied intraperitoneally in a dose of 100 mg/kg.

The main aim of our study was to evaluate the effect of MMF on uveitis in the mouse model of EAU. MMF is an antimetabolite which reversibly inhibits purine biosynthesis necessary for B- and T-cell growth. The treatment of non-infectious uveitis with MMF was proved successful in several reported case series in humans: Siepmann (2006), Teoh et al. (2008), Daniel et al. (2010) or Doycheva et al. (2011). Its effect in uveitis, however, is not as marked as in corneal diseases (Zierhut et al.,

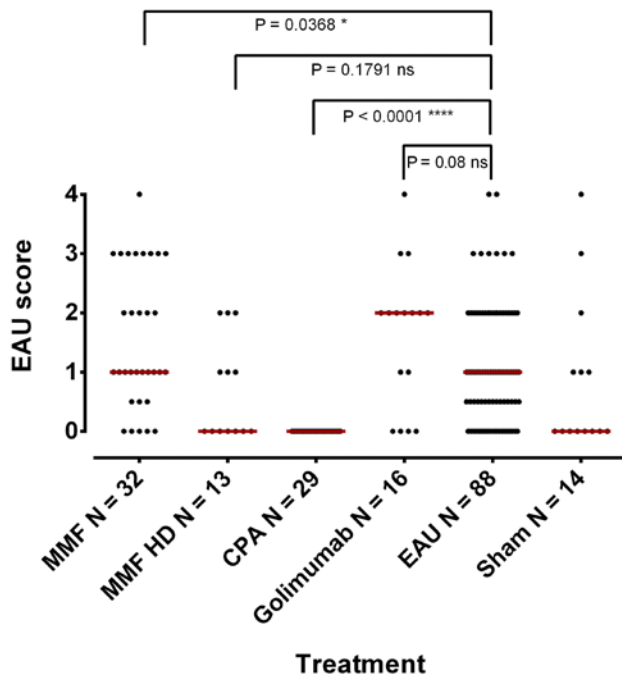


Fig. 10. The effectivity of EAU treatments. Comparison of the inflammation score (grade 0 to 4) acquired by histological evaluation on day 35 post immunization in the treated groups and eyes with EAU without treatment. The medians are displayed as red lines. The comparison between the groups was assessed using Mann-Whitney statistical test and the results are represented by ns, stands for non-significant, and significant outcomes that are displayed as * ($P < 0.05$) and **** ($P < 0.0001$). The median of inflammation score in EAU untreated mice is 1.0.

Abbreviations: MMF – mycophenolate mofetil, HD – high dose, N – number of eyes, CPA – cyclophosphamide, EAU – experimental autoimmune uveitis.

2005). In the literature even rather low success rate of uveitis therapy with MMF is reported as successful. In the everyday practice, MMF has got its place among the variety of immunosuppressants, and for some types of uveitis, it is recommendable. The main role of MMF is, however, rather supportive, and its effect in monotherapy in sight-threatening uveitis is more than questionable.

We have therefore tested MMF effects in the experimental model of uveitis. In the past, MMF was used in the EAU model in Lewis rats, and EAU induction was performed by bovine S-antigen (Chanaud et al., 1995; Dick et al., 1998). The rats were gavage fed with 30 mg/kg/day MMF on days 0–13 after immunization, which markedly suppressed the inflammation. In the control group 10 of 11 rats developed severe inflammatory changes; in the treated group 2 of 11 rats developed disease of lower intensity and later onset. Dick et al. (1998) also immunized the Lewis rats with bovine antigen and MMF was applied using gastric lavage in a dose of 30 mg/kg/day on days 7 to 20. The rats displayed a delay in disease onset with reduced clinical severity scores (1.38) compared to the control group (3.4) and animals developed a second peak of clinical disease around the day

28–32 post immunization. Histologic examination showed protection of photoreceptor loss in outer segments with MMF treatment. However, to date MMF has not been applied in the mouse EAU model. In our study, two dose regimens of MMF were used, one which better reflects the human dosage of this drug (30 mg/kg) and one with a higher dose (50 mg/kg). The lower dose of MMF suppressed experimental uveitis to a degree of statistical significance ($P < 0.05$) when compared to the sham treated group of EAU mice and of EAU untreated mice. The higher dose did not reach statistical significance, presumably because of a comparison with a higher number of control eyes examined (13 eyes with 50 mg/kg MMF versus 88 eyes with EAU).

Golimumab is a humanized anti-TNF- α monoclonal antibody approved for treatment of inflammatory bowel disease since 2013. The advantage of golimumab compared to other anti-TNF- α is the application which is performed subcutaneously once a month. Promising results in humans were described in a case series with severe autoimmune uveitis (Miserocchi et al., 2013). There are no reports published concerning golimumab in the EAU rodent model, as this drug should have no effect on rodents due to its humanized structure. Our observation shows rather enhancement of uveitis in the treatment group, which however did not reach statistical significance. Our hypothesis about the enhanced pro-inflammatory effect of golimumab is that the fully humanized antibody anti-TNF- α applied to mice causes a strong immunological reaction.

The establishment of a reproducible model of experimental autoimmune uveitis opens up many research possibilities. Uveitis induced in the C57BL/6 mouse strain is mild and chronic and closely resembles autoimmune uveitis in humans. In this study, we have confirmed the efficacy of CPA therapy for posterior uveitis. Our results show statistically significant suppression of experimental uveitis with MMF, which supports its use in human medicine. The model of EAU in mice is a very useful template for novel therapeutic approaches in the future.

Acknowledgements

The authors thank Professor Hassan Farghali (Institute of Pharmacology, First Faculty of Medicine, Charles University in Prague and General University Hospital in Prague, Czech Republic) and his laboratory team for the menagerie support and laboratory facility. The authors thank Professor John Forrester and his team (Institute of Medical Science, University of Aberdeen, UK) for their kind help with establishing the EAU model.

References

- Avichezer, D., Silver, P. B., Chan, C. C., Wiggert, B., Caspi, R. R. (2000) Identification of a new epitope of human IRBP that induces autoimmune uveoretinitis in mice of the H-2b haplotype. *Invest. Ophthalmol. Vis. Sci.* **41**, 127-131.
- Broderick, C., Hoek, R. M., Forrester, J. V., Liversidge, J., Sedgwick, J. D., Dick, A. D. (2002) Constitutive retinal

- CD200 expression regulates resident microglia and activation state of inflammatory cells during experimental autoimmune uveoretinitis. *Am. J. Pathol.* **161**, 1669-1677.
- Caspi, R. R., Roberge, F. G., Chan, C. C., Wiggert, B., Chader, G. J., Rozenszajn, L. A., Lando, Z., Nussenblatt, R. B. (1988) A new model of autoimmune disease. Experimental autoimmune uveoretinitis induced in mice with two different retinal antigens. *J. Immunol.* **140**, 1490-1495.
- Caspi, R. R., Chan, C. C., Wiggert, B., Chader, G. J. (1990a) The mouse as a model of experimental autoimmune uveoretinitis (EAU). *Curr. Eye Res.* **9 (Suppl)**, 169-174.
- Caspi, R. R., Chan, C. C., Leake, W. C., Higuchi, M., Wiggert, B., Chader, G. J. (1990b) Experimental autoimmune uveoretinitis in mice. Induction by a single eliciting event and dependence on quantitative parameters of immunization. *J. Autoimmun.* **3**, 237-246.
- Chanaud, N. P., Vistica, B. P., Eugui, E., Nussenblatt, R. B., Allison, A. C., Gery, I. (1995) Inhibition of experimental autoimmune uveoretinitis by mycophenolate mofetil, an inhibitor of purine metabolism. *Exp. Eye Res.* **61**, 429-434.
- Daniel, E., Thorne, J. E., Newcomb, C. W., Pujari, S. S., Kaçmaz, R. O., Levy-Clarke, G. A., Nussenblatt, R. B., Rosenbaum, J. T., Suhler, E. B., Foster, C. S., Jabs, D. A., Kempen, J. H. (2010) Mycophenolate mofetil for ocular inflammation. *Am. J. Ophthalmol.* **149**, 423-432.e1-2.
- Dick, A. D., Cheng, Y. F., Liversidge, J., Forrester, J. V. (1994) Immunomodulation of experimental autoimmune uveoretinitis: a model of tolerance induction with retinal antigens. *Eye (Lond)*, **8 (Pt 1)**, 52-59.
- Dick, A. D., Kreutzer, B., Laliotou, B., Forrester, J. V. (1998) Effects of mycophenolate mofetil on nasal mucosal tolerance induction. *Invest. Ophthalmol. Vis. Sci.* **39**, 835-840.
- Doycheva, D., Zierhut, M., Blumenstock, G., Stuebiger, N., Deuter, C. (2011) Long-term results of therapy with mycophenolate mofetil in chronic non-infectious uveitis. *Graefes Arch. Clin. Exp. Ophthalmol.* **249**, 1235-1243.
- Durrani, O. M., Meads, C. A., Murray, P. I. (2004) Uveitis: a potentially blinding disease. *Ophthalmologica* **218**, 223-236.
- Forrester, J. V., Liversidge, J., Dua, H. S., Towler, H., McMenamin, P. G. (1990) Comparison of clinical and experimental uveitis. *Curr. Eye Res.* **9 (Suppl.)**, 75-84.
- Forrester, J. V., Liversidge, J., Dua, H. S., Dick, A., Harper, F., McMenamin, P. G. (1992) Experimental autoimmune uveoretinitis: a model system for immunointervention: a review. *Curr. Eye Res.* **11 (Suppl.)**, 33-40.
- Khan, I. J., Barry, R. J., Amissah-Arthur, K. N., Carruthers, D., Elamanchi, S. R., Situnayake, D., Murray, P. I., Denniston, A. K., Rauz, S. (2013) Ten-year experience of pulsed intravenous cyclophosphamide and methylprednisolone protocol (PICM protocol) in severe ocular inflammatory disease. *Br. J. Ophthalmol.* **97**, 1118-1122.
- Miserocchi, E., Modorati, G., Pontikaki, I., Meroni, P. L., Gerloni, V. (2013) Long-term treatment with golimumab for severe uveitis. *Ocul. Immunol. Inflamm.* **22**, 90-95.
- Mochizuki, M., Nussenblatt, R. B., Kuwabara, T., Gery, I. (1985) Effects of cyclosporine and other immunosuppressive drugs on experimental autoimmune uveoretinitis in rats. *Invest. Ophthalmol. Vis. Sci.* **26**, 226-232.
- Paques, M., Guyomard, J. L., Simonutti, M., Roux, J. M., Picaud, S., Le-Gargasson, J. F., Sahel, J. A. (2007) Panretinal, high resolution color photography of the mouse fundus. *Invest. Ophthalmol. Vis. Sci.* **48**, 2769-2774.
- Siepmann, K., Huber, M., Stübiger, N., Deuter, C., Zierhut, M. (2006) Mycophenolate mofetil is a highly effective and safe immunosuppressive agent for the treatment of uveitis: a retrospective analysis of 106 patients. *Graefes Arch. Clin. Exp. Ophthalmol.* **244**, 788-794.
- Suelles, A. M., Arcinue, C. A., González-Martin, J. M., Kruh, J. N., Foster, C. S. (2013) Analysis of a novel protocol of pulsed intravenous cyclophosphamide for recalcitrant or severe ocular inflammatory disease. *Ophthalmology* **120**, 1201-1209.
- Suttrop-Schulten, M. S., Rothova, A. (1996) The possible impact of uveitis in blindness: a literature survey. *Br. J. Ophthalmol.* **80**, 844-848.
- Suzuki, I., Takahashi, S., Fujii, Y., Fuyama, S., Arai, S. (1989) Experimental autoimmune uveoretinitis (EAU) in rats: isolation of S-antigen, EAU susceptibility of rat strains, genetic control of EAU induction, and effects of cyclophosphamide and irritation on EAU. *Jpn. J. Ophthalmol.* **33**, 13-26.
- Teoh, S. C., Hogan, A. C., Dick, A. D., Lee, R. W. (2008) Mycophenolate mofetil for the treatment of uveitis. *Am. J. Ophthalmol.* **146**, 752-60.
- Thurau, S. R., Chan, C. C., Nussenblatt, R. B., Caspi, R. R. (1997) Oral tolerance in a murine model of relapsing experimental autoimmune uveoretinitis (EAU): induction of protective tolerance in primed animals. *Clin. Exp. Immunol.* **109**, 370-376.
- Xu, H., Koch, P., Chen, M., Lau, A., Reid, D. M., Forrester, J. V. (2008) A clinical grading system for retinal inflammation in the chronic model of experimental autoimmune uveoretinitis using digital fundus images. *Exp. Eye Res.* **87**, 319-326.
- Zierhut, M., Stübiger, N., Siepmann, K., Deuter, C. M. (2005) MMF and eye disease. *Lupus* **14 (Suppl 1)**, 50-54.