

Original Article

Expression of Prostaglandin-Synthesizing Enzymes (Cyclooxygenase 1, Cyclooxygenase 2) in the Ovary of the Quail (*Coturnix japonica*)

(quail / ovary / cyclooxygenase / immunocytochemistry / *in situ* hybridization / PCR)

D. RODLER, F. SINOWATZ

Institute of Anatomy, Histology and Embryology, Department of Veterinary Sciences, Ludwig-Maximilians University Munich, Germany

Abstract. Cyclooxygenase is known to be the rate-limiting enzyme in the production of prostaglandins. So far, in different bird species there have been found two isoforms of cyclooxygenases (COX), cyclooxygenase 1 (COX-1) and cyclooxygenase 2 (COX-2). These isoforms along with prostaglandins are regarded to possess a determining influence on the success in female reproduction. Only in a few bird species the expression sites of cyclooxygenases have been investigated. In this study we report on the expression of COX-1 and COX-2 in the ovary of the quail (*Coturnix japonica*) using PCR, immunohistochemistry and non-radioactive *in situ* hybridization techniques. Using real time-polymerase chain reaction (RT-PCR), a distinct signal for COX-1 and COX-2 could be shown in small and large follicles of quail ovary. Antibodies to COX-1 distinctly labelled smooth muscle cells of the stroma, whereas COX-2 showed marked immunostaining in the thecal glands and the ovarian surface epithelium. In the same location, a signal of the corresponding mRNAs of COX-1 and COX-2 was found using *in situ* hybridization. This expression pattern in the quail is therefore completely different from the localization of COX-1 and COX-2 in the hen and ostrich, which suggests differ-

ent functions of the cyclooxygenases in this small galliform avian species. According to our results, in quails COX-2 is involved in the synthesis of prostaglandins in the ovary's interstitial glands, which until now have been considered mainly as steroid-secreting cells. COX-1, which is expressed in the smooth muscles of the stroma, possibly plays a role in ovulation.

Introduction

Cyclooxygenase (COX) enzymes are required for many female reproduction and ovarian functions in mammals (Song et al., 1998). They are rate-limiting enzymes in the production of prostaglandins. There are two isoforms existent, the constitutively expressed cyclooxygenase 1 (COX-1) and the usually induced form, cyclooxygenase 2 (COX-2). Possessing two separate but linked active sites, COX catalyses the bis-deoxygenation and subsequent reduction of arachidonic acid (AA) to an intermediate prostaglandin (PG), PGH₂. Downstream enzymes, such as PGE synthase, convert PGH₂ to a family of PGs, each member of which exerts a range of physiologic effects through G-protein-coupled receptors (Coleman et al., 1994; Narumiya et al., 1999). COX-1 is usually involved in homeostatic functions, while COX-2 has been implicated in pathological processes such as inflammation and cancer (Smith et al., 2000). The synthesized prostaglandins mainly participate in inflammation, pain, fever and contractions of the smooth muscle cells. In birds, the contractions of smooth muscle cells in the ovary seem to be required to accomplish ovulations in the ovary. Sasanami et al. (2015) recently demonstrated the role of PGF₂α, which is produced in the cloacal glands of the male quail, for successful fertilization. During mating it induces vaginal contractions in the female bird, which causes opening of the sperm storage tubules and enhancing fertility. Furthermore, ovulations have been linked to an inflammatory response that also rises the amount of prostaglandins, and therefore of COX.

Despite evidence implicating that cyclooxygenases are critical factors in female reproduction, little is known

Received June 1, 2015. Accepted June 9, 2015.

Corresponding author: Fred Sinowatz, Institute of Anatomy, Histology and Embryology, Department of Veterinary Sciences, Ludwig-Maximilians University Munich, Veterinaerstrasse 13, D-80539 Munich, Germany. Phone: +49-89-21805852; Fax: +49-89-21802569; e-mail: f.sinowatz@anat.vetmed.uni-muenchen.de

Abbreviations: AA – arachidonic acid, ABC – avidin-biotin complex, BP – base pairs, GC – granulosa cells, NCBI – National Center for Biotechnology Information, COX – cyclooxygenase, IGC – interstitial gland cells, LH – luteinizing hormone, NSAID – non-steroid anti-inflammatory drugs, OOP – ooplasm, OSE – ovarian surface epithelium, PG – prostaglandin, POF – primordial follicle, PRF – preovulatory follicle, PVF – previtellogenic follicle, RT-PCR – real time-polymerase chain reaction, SSC – saline sodium citrate, ST – ovarian stroma, VF – vitellogenic follicle.

about COX expression in the vertebrate ovary. Studies in mammalian ovaries suggest that prostaglandins produced by COX may be involved in different ovarian reproduction processes (Sirois et al., 2004). Less is still known about the folliculogenesis and ovulation in birds. In avian species, cyclooxygenases have so far been studied only in the domestic hen (*Gallus domesticus*) (Hales et al., 2008) and ostrich (*Struthio camelus*) (Rodler and Sinowatz, 2015). Overexpression of COX has been correlated with distinct pathological changes, such as several types of carcinomas. This overexpression of COX-1 but not COX-2 has been shown to be associated with ovarian cancer of the chicken (Hales et al., 2008). In the mammalian ovary, COX-1 is confined to the corpus luteum and interstitial thecal cells (Sirois and Richards, 1993). In the chicken ovary, COX-1 is mainly localized to the granulosa cell layers of follicles and the ovarian surface epithelium. Contrary to the hen, COX-1 is only found in the ooplasm of the oocyte and appears neither to be involved in ovulation nor in oviposition in the ostrich (Rodler and Sinowatz, 2015). In the mammalian ovary, COX-2 is expressed in granulosa cells (Sirois and Richards, 1993), whereas in the hen COX-2 is additionally highly expressed in the interstitial tissue of the ovary (Hales et al., 2008). The expression of COX-2 in granulosa cells and some stroma cells accords with the ostrich too, but with a supplemental high COX-2 immunopositive ovarian surface epithelium. The authors conclude that COX-2 is very well involved in the ovarian maturation process in this bird species and that the expression of COX-2 is necessary for certain stages of oocyte nuclear maturation (Rodler and Sinowatz, 2015).

In our study we examined the location and expression of COX in the ovary of the Japanese quail (*Coturnix japonica*) as a small galliform bird species and role model for studies at the avian ovary. The quail shows a completely different expression pattern of COX-1 and COX-2 compared to the hen and ostrich, which also suggests different functions of the cyclooxygenases in this avian species.

Material and Methods

Animal and tissue preparation

Twenty-five healthy female 6-month-old Japanese quails (*Coturnix japonica*) were used in this study. The birds had been provided by the Institute of Veterinary Nutrition, Department of Veterinary Sciences, Ludwig-Maximilians University Munich, Germany. All birds were housed as indoor breeders and were fed with a commercial diet and water *ad libitum*. Since no experi-

mental procedures were involved in this study, the German Law on Animal Welfare (§§8b, 9.2) and the Animal Care Committee of the Veterinary Faculty of the University of Munich authorized the sacrifice of these Japanese quails for scientific use. Under CO₂ anaesthesia, the quails were decapitated and their ovaries removed and fixed in Bouin's solution (1500 ml picric acid, 500 ml glacial acetic acid, 100 ml 37% formalin) for 14 h. Then, appropriate tissue samples of different follicular sizes of the ovary were cut and dehydrated in a graded series of ethanol and embedded, using an automatic tissue processor (Shandon Duplex Processor, Frankfurt, Germany) and a Histostat Tissue Embedding Centre (Reichert-Jung, Vienna, Austria). Five-micrometre paraplast sections were cut by using a rotary microtome (Leitz Microm HM 340E, Wetzlar, Germany). The sections were collected on glass slides (Menzel-Glaeser, Braunschweig, Germany).

RT-PCR

RNA extraction and cDNA synthesis: preovulatory and small yellow follicles were removed from quail ovaries prior to homogenization and RNA extraction. Total RNA was isolated from the tissue samples using the RNeasy FFPE Kit (Qiagen, Hilden, Germany) and quantified by determination of absorbance at A₂₆₀. All RNA samples used in this study had a 260 : 280 ratio between 1.9 and 2.05. RNA samples were then treated with RQ1 RNase-free DNase prior to reverse transcription. cDNA synthesis of the extracted total RNA eluted was carried out with Super Script cDNA Synthesis Kit (BioRad, Munich, Germany) according to the instructions of the manufacturer. The absence of genomic DNA in each RNA sample was confirmed by a minus-reverse transcriptase ("–RT") control. The "–RT" control is a mock reverse transcription containing all the RT-PCR reagents, with the exception of reverse transcriptase. The presence of an amplification product in the "–RT" control is therefore indicative of contaminating DNA in the sample. The cDNA synthesis was in line with the procedure of earlier investigations (Wendl et al., 2012).

Primer design

The following mRNA sequences were retrieved from NCBI: <http://www.ncbi.nlm.nih.gov/pubmed/> – nucleotide for the following genes: chicken cyclooxygenase-1 and cyclooxygenase-2. Primer pairs were designed by using the "pick primers" option of the respective mRNA display (<http://www.ncbi.nlm.nih.gov/nucore>), in order to simultaneously show the exon constellation of forward and reverse primers. Primer pairs were chosen to generate PCR products between 100 and 170 bp. The sequences used for primer design are shown in Table 1 (β -actin

Table 1. RT-PCR: Used primers: chicken (*Gallus gallus*)

Primers	Forward primer	Reverse primer	Product size (bp)	GenBank accession No.
COX-1	CAACGGCATCTTTGGGGAAA	CTCCAGGGATGCTGTCTTGA	154	NC_006104.3
COX-2	GGACGGGCTATTATGGGGAA	ACGTGAAGAATTCCGCTGTG	155	NC_006095.3

was used only as an internal system control). All primer pairs were designed in an intron-flanking fashion, the intron forced to be larger than 1000 bp, thus excluding the possibility of amplifying genomic DNA through our PCR protocol. The primers were synthesized by MWG-Biotech (Ebersberg, Germany). For RT-PCR, the concentration of the primer sets was adjusted to 1.2 pmol/ μ l.

End-point RT-PCR

Using specific primer pairs (Table 1), sequences of the genes of interest were amplified by end-point PCR. RNA quality of isolated RNA was evaluated using the microfluid-based automated electrophoresis system Experion (BioRad, Munich, Germany). Reaction volumes for a total of 15 μ l per well were set up, containing 7.5 μ l of EVAGreen Mastermix (BioRad), 3 μ l of cDNA template and 4.5 μ l of primer pairs (0.4 mM primer reverse and forward). Non-template controls were performed with each primer pair by substituting cDNA in the above set-up by double-distilled water. PCR was performed using iCycler EvaGreen[®] protocol (Bio-Rad) in a 96-well plate. The PCR thermal cycling program was accomplished by a two-step temperature protocol with the following conditions: (first phase) 95 °C for 1.45 min for enzyme activation and (second phase) 40 cycles at 95 °C for 15 s (denaturation) and 60 °C for 30 s (annealing and extension). To reduce the effects of pipetting errors, all samples were amplified in triplicates. Parallel reactions without templates (distilled water) were used as negative controls. To identify and validate the different PCR amplification products, we ran them in 1.5% agarose gel (Biozym Phor Agarose, Biozym Scientific GmbH, Oldendorf, Germany). The gels were stained using Gel Red Nucleic Acid Stain (VWR, Darmstadt, Germany). The position of the bands was compared with a DNA Sizer XII marker (Peqlab, Erlangen, Germany).

Non-radioactive *in situ* hybridization (NISH)

In situ hybridization was performed using a standard protocol used in our laboratory. Small pieces of ovarian tissue (side length: 5 mm) were fixed in 3.7% formalin for 12 h and embedded in paraffin wax. Serial sections (5 μ m) were mounted on amino propylene ethoxysilane-coated slides and dried at 50 °C. All steps during *in situ* hybridization were conducted under strict RNase-free conditions, and all solutions for RNA *in situ* hybridization were prepared using diethylpyrocarbonate (DEPC)-treated water. Sections were deparaffinized with xylene (3 \times 10 min), immersed in absolute ethanol (2 \times 5 min), and air-dried. Immediately after drying, the sections

were dipped in 2% saline sodium citrate (SSC) prewarmed in a water bath (80 °C) for 10 min, followed by cooling off for 20 min at room temperature. Slides were then sequentially washed in distilled water (2 \times 5 min) and Tris buffer (pH 7.4; 2 \times 5 min) and incubated for 20 min with 0.05% proteinase E (VWR, Ismaning, Germany) in Tris buffer at room temperature. Sections were subsequently washed in Tris buffer (2 \times 5 min) and distilled water (2 \times 5 min) and postfixed for 10 min in freshly prepared 4% paraformaldehyde/PBS (pH 7.4). After further washing in PBS (2 \times 5 min) and distilled water, slides were dehydrated in an ascending graded series of ethanol and air-dried. Oligonucleotide probes labelled with biotin were diluted with RNA hybridization buffer (DAKO, Munich, Germany) to a final concentration of 5 pmol/ml. Hybridization was carried out by overlaying the dry sections with 40 μ l of the hybridization mixture. Incubation was done under a cover slip in a humidified chamber at 38 °C overnight. Then, slides were washed in SSC (2 \times 15 min) prewarmed to 38 °C, distilled water (2 \times 5 min), and Tris buffer (2 \times 5 min). Detection of transcripts was performed using a streptavidin-biotin-peroxidase complex kit and diaminobenzidine (DAKO Deutschland GmbH, Hamburg, Germany) according to the manufacturer's instructions. For negative controls, parallel sections were hybridized either with the sense oligonucleotide probe or with buffer alone. Tissue from bovine uterus was used as a positive control. The used antisense and sense biotinylated oligonucleotides for COX-1 and COX-2 are shown in Table 2.

Immunohistochemistry

Paraffin sections were dewaxed and then washed three times for 5 min with PBS buffer at pH 7.4. Sections for COX-1 were pre-treated with 10 mM sodium citrate buffer at pH 6.0 (9 ml 0.1 M citric acid and 41 ml 0.1 M sodium citrate (Merck, Germany) diluted in 500 ml distilled water) in a microwave oven with a power of 600 W for 3 \times 10 min. Endogenous peroxidase activity was blocked with 7.5% H₂O₂ (diluted in distilled water) at room temperature for 10 min. Non-specific antibody binding was blocked with Dako Protein Block Serum Free (Dako Deutschland) for 10 min. The sections were incubated with polyclonal primary antibodies against COX-1 (diluted 1 : 250, host rabbit, ab53766 (256); Abcam, Cambridge, UK) and COX-2 (diluted 1 : 400, host goat, ab23672 (266); Abcam) at 6 °C overnight (immunogens: synthetic peptides derived from human COX-1/COX-2). Localization of the antigen was achieved using the avidin-biotin complex (ABC) technique

Table 2. *In situ* hybridization: used antisense and sense biotinylated oligonucleotides

Oligonucleotides	Sense / Antisense	Alias	Label	Gene bank	Material
COX-1	5'tca ggt ggt tct ggg aca tca 3'	sense	5'-biotin	XM_425326	chicken specific
	5'tgt agc cgt act ggg agt tga a 3'	antisense			
COX-2	5'ctg ctc cct ccc atg tca ga 3'	sense	5'-biotin	XM_422297	chicken specific
	5'cac gtg aag aat tcc ggt gtt 3'	antisense			

(Hsu et al., 1981; Romeis, 2004). The appropriate biotinylated secondary antibodies against COX-1 (diluted 1 : 300, anti-rabbit from pig; Dako) and COX-2 (diluted 1 : 400, anti-goat from rabbit; Dako) were incubated with the sections for 16 h at room temperature.

Subsequently, treatment with StreptABCComplex/HRP (Dako) was performed for 30 min at room temperature, and treatment with 1 mg/ml 3,3'-diaminobenzidine tetrahydrochloride (DAB tablets, 10 mg; Biotrend Chemikalien, Köln, Germany) was performed for 5 min. All of the incubations were performed in a humidified chamber. Sections were either left unstained or were counterstained with haematoxylin (20 s), dehydrated, and mounted with Eukitt quick-hardening mounting medium for microscopy (Fluka Analytical®, Sigma-Aldrich Laborchemikalien Seelze, Germany).

Negative controls were performed by either replacing the primary antibody with buffer or non-immune serum, or by incubating with the 3,3'-diaminobenzidine reagent alone to exclude the possibility of detecting non-suppressed endogenous peroxidase activity. A lack of detectable staining in the negative controls demonstrated that the reactions were specific. The images were captured with a Leica Labo-Luxâ microscope equipped with a Zeiss Axiocamâ camera (Zeiss, Munich, Germany). As positive controls, ovarian tissue from several mammalian species (bovine, dog) of proven immunoreactivity was used.

On the basis of visual examination of two independent observers, the relative intensities of COX-1 and COX-2 immunostaining were designated as negative (-), weak (-/+), distinct (++) and strong (+++). The results evaluating the intensity qualities are summarized in Table 3.

Results

Structure and immunostaining results in the quail ovary

The ovary of the quail was found typically "birdlike" and was composed of the cortex, medulla, and ovarian stalk. Mature laying quails possess huge protruding follicles, which give the ovary a grape-shaped appearance. Additionally, the ovarian cortical region is partially divided into compartments due to deep surface crypts. The follicles, although depending on the size and development, are mainly located inside the cortex, whereas the medulla and ovarian stalk include nerve bundles and blood vessels. Among them, primordial (smallest, POF),

previtellogenic (white yolk, PVF), vitellogenic (yellow yolk, VF) and preovulatory follicles (largest, due to ovulation, PRF) could be distinguished at this bird's ovary.

The smallest of all stages, called primordial follicles, were distributed in the peripheral area of the cortex just beneath the ovarian surface epithelium and ranged from 40 to 65 µm in size. This follicle type was composed of a primary oocyte, which was enclosed by flat or cuboidal granulosa cells. In the outer periphery, a layer of fibroblasts with interspersed melanocytes surrounded it. As in most studied avian species, a conspicuous avian feature, the Balbiani body, which consists of an eccentric concentration of organelles, could be found in the ooplasm adjacent to the nuclear membrane. The chromosomes could be seen easily inside the relatively huge nucleus, due to showing lampbrush configuration.

Previtellogenic follicles, which could be divided into early previtellogenic stages (65 to 450 µm) and late previtellogenic stages (450 to 800 µm), were also often located near the ovarian surface epithelium or in the deeper regions of the cortex. Their single-layered granulosa cells became stratified, but got cuboidal again with follicular maturation.

Vitellogenic and preovulatory follicles (up to 15 mm) have incorporated a large amount of yolk in the ooplasm, which is why they are often referred to as "yellow follicles". They are surrounded by a single monolayer of cuboidal to flat granulosa cells sitting upon a distinct basement membrane. Inner and outer thecal layers that are composed of fibroblasts and smooth muscle cells surround these follicles.

Transformed thecal and granulosa cells were found around all follicular stages, forming clusters of interstitial glands. They are hypothesized to work as equivalents to the mammalian corpus luteum.

The adult ovary of the quail also contains a well-developed lacunar system in which peritoneal fluid is taken up. The majority of the small follicles have a very superficial localization in the cortex. Groups of smooth muscle cells surround the lacuno-peritoneal communication channels in the neighbourhood of the hilar region. There, the ovarian surface epithelium (containing round nuclei) is directly continuous with the lining epithelium (containing much flattened nuclei) of the communication channels.

An intermediate to strong immunostaining for COX-1 was seen in the cytoplasm of the smooth muscle cells of the stroma (Fig. 1a), which usually showed its strongest expression in the perinuclear area of the cells (Fig. 1b).

Table 3. Immunohistochemistry results: staining intensity of different ovarian structures

Antibody	Primordial follicle			Previtellogenic follicle			Vitellogenic follicle				Other ovarian tissue				
	GC	OOP	BB	TH	GC	OOP	TE	TI	GC	OOP	SM	V	ISG	OSE	TA
COX-1	-	-	-	+	-	-	+	+	-	-	++	-	-	+	-
COX-2	-/+	-	+	-	-/+	-	+	+	-/+	-	-	-	++	+	-

Legend: - = negative; -/+ = weak; + = distinct; ++ = strong

BB = Balbiani body, GC = granulosa cells, ISG = interstitial glands, OOP = ooplasm, OSE = ovarian surface epithelium, SM = smooth muscle cells, TH = theca around previtellogenic follicles, TE = theca externa, TI = theca interna, TA = tunica albuginea, V = vessel

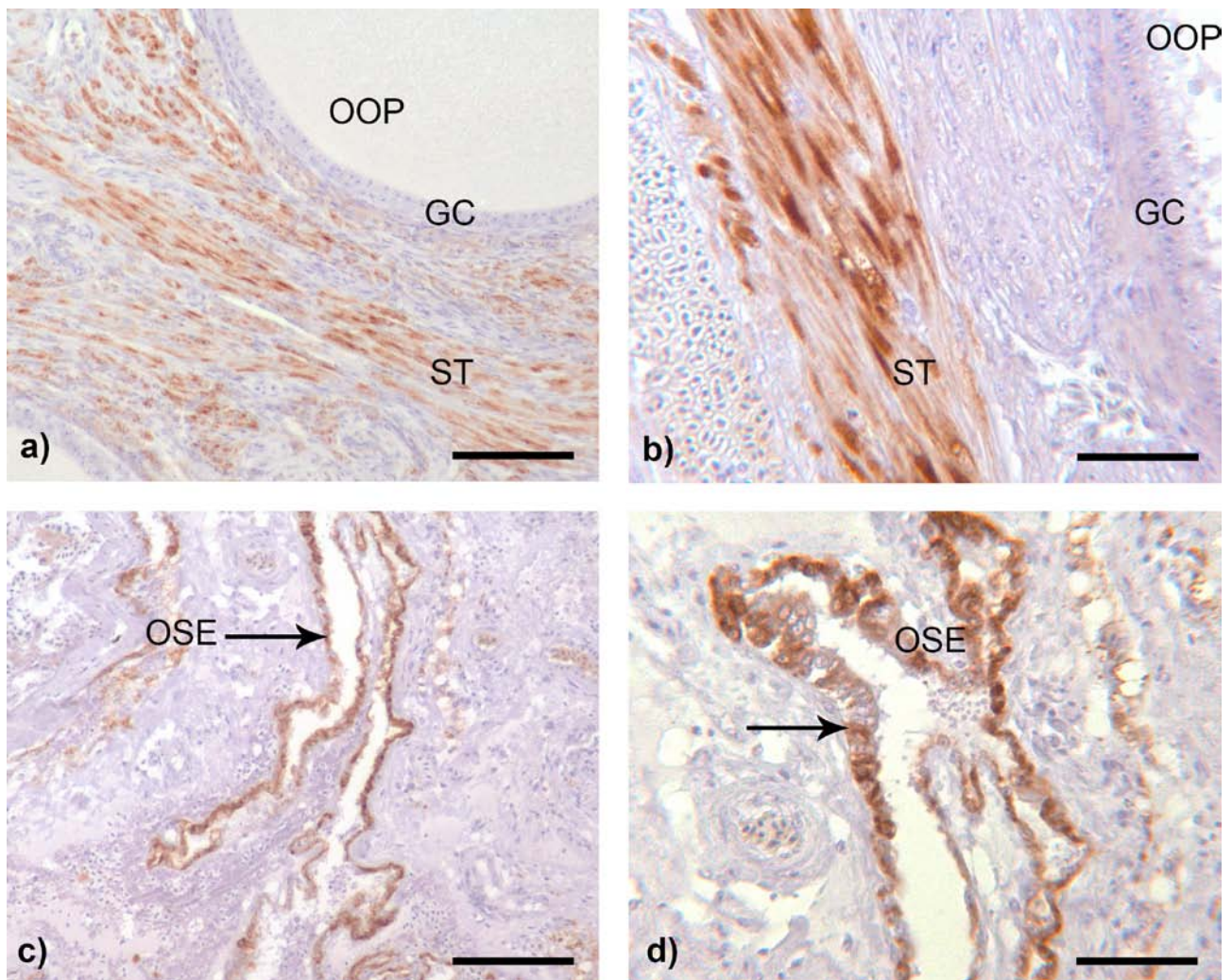


Fig. 1. Immunohistochemical localization of COX-1

a) The smooth muscle cells that are distributed throughout the ovarian stroma (ST) or surround previtellogenic follicles displays a distinct reaction with the COX-1 antibody. GC = granulosa cells; OOP = ooplasm. **b)** At higher magnification it becomes obvious that the immunostaining for COX-1 is mostly localized in the cytoplasm near to the nucleus of the smooth muscle cells and can be seen in the thecal stroma (ST) around this vitellogenic follicle. GC = granulosa cells; OOP = ooplasm. **c)** The ovarian surface epithelium (OSE), which protrudes with numerous crypts into the stroma of the cortex ovarii, is usually distinctly COX-1 positive. **d)** At higher magnification it can be noticed that several ovarian surface epithelial cells (OSE) remain unstained, while the cytoplasm of others (arrow) shows strong immunostaining with the COX-1 antibody. Scale bars: **a** = 100 μ m; **b** = 50 μ m; **c** = 100 μ m; **d** = 50 μ m

Also the ovarian surface epithelium was distinctly COX-1-positive (Fig. 1c, d). In contrast, the different stages of follicular development (previtellogenic and vitellogenic follicles) did not display any immunostaining for COX-1, neither in their oocytes nor in their follicular wall.

A rather different immunostaining pattern compared to COX-1 could be demonstrated for COX-2: distinct immunostaining was found in many but not all of the polygonal steroid-producing interstitial gland cells (IGCs, Fig. 2a). The outer cell layer of the interstitial glands (enclosing cells), which consists of oval to elongated cells with an oval nucleus, usually was only slightly positive (Fig. 2b). The interstitial gland cells, also referred to as interstitial/thecal glands, which are regarded as the avian equivalents to the mammalian corpus luteum in the ovary, were easily identifiable both in haematoxylin-

eosin and the immunostained sections. They appeared as islets of epithelial cells located in the intra-ovarian stroma forming spherical or sometimes elongated glands, usually containing two cell types, steroid hormone-producing cells and enclosing cells. Several glands were distributed throughout the whole circumference of the follicles. Differences in the amount of lipid content between interstitial glands were obvious, but none of the thecal cells showed immunostaining for COX-1. COX-2 was also present in the ovarian surface epithelium (Fig. 2c). The growing oocytes as well as the outer cell layers of the follicular wall (theca interna and externa) were always negative for COX-2. Slight staining was detected in the granulosa cells in primordial and small previtellogenic follicles with colour signals getting decreased with follicular maturation (Fig. 2d). No COX-2 immu-

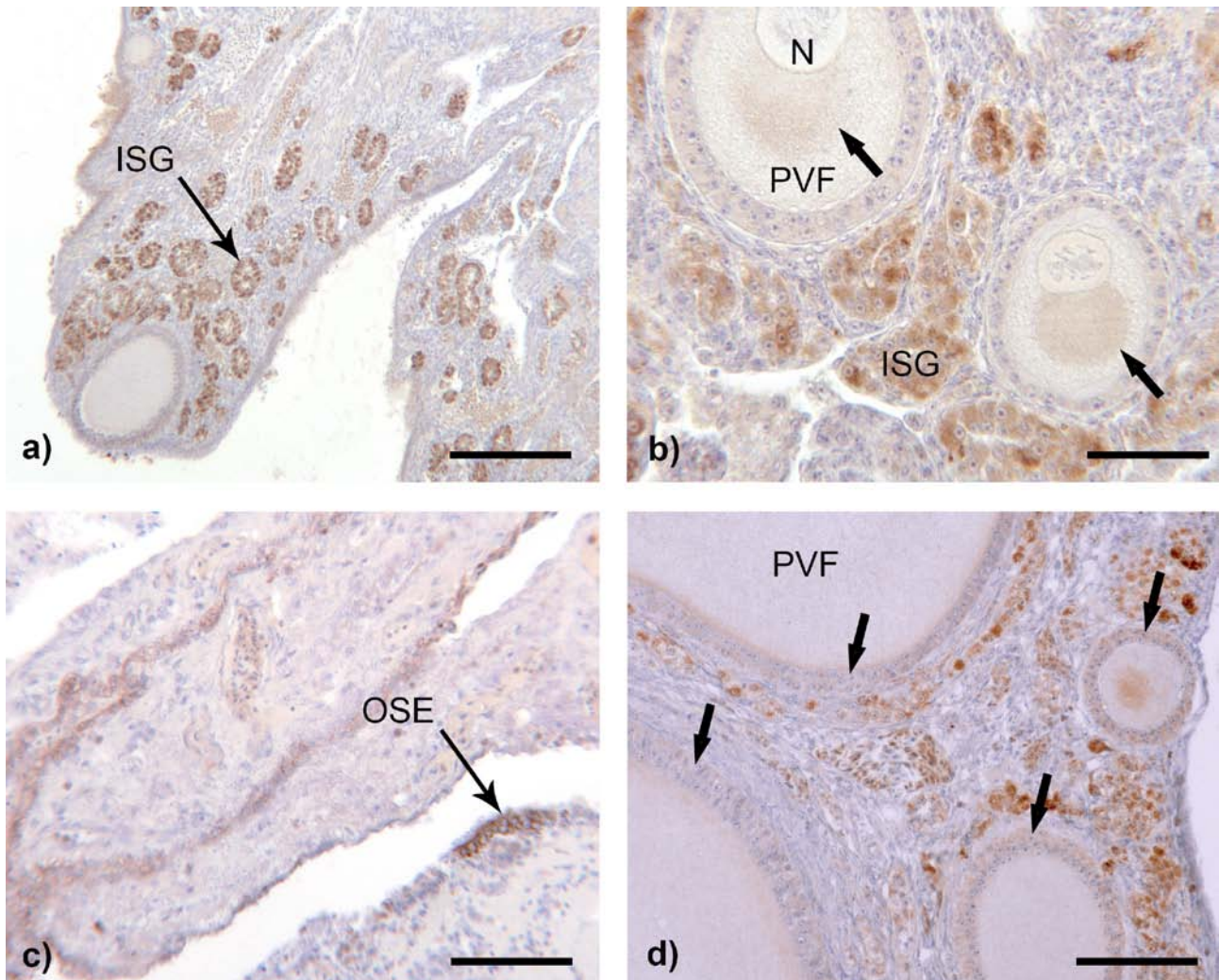


Fig. 2. Immunohistochemical localization of COX-2

a) The interstitial gland cells (ISG) are mostly organized in clusters and are strongly immunopositive for COX-2. **b)** At higher magnification, the positive COX-2 immunostaining appears concentrated at the area adjacent to the nucleus. A moderate reaction of the yolk precursor material in the area of the Balbiani bodies of early previtellogenic follicles can be noticed (arrows). **c)** Similar to COX-1, the ovarian surface epithelium possesses many COX-2-positive cells, although not all of them immunostain with the same intensity. **d)** While a reaction in the granulosa cells with COX-1 remains negative at all follicular stages, the situation with COX-2 in these cells is evaluated with weak positivity (arrows). The reactions with COX-2 decreased with follicular maturation from weak to almost non-existent staining quality.

Scale bars: **a** = 100 μm ; **b** = 40 μm ; **c** = 75 μm ; **d** = 100 μm

nostaining was found in the endothelium of the blood vessels and the smooth muscle cells of the stroma.

RT-PCR

Using RT-PCR, a distinct signal for COX-1 and COX-2 could be shown in samples of the quail ovary (Fig. 3). Both small and large follicles showed a band of the expected molecular weight.

Non-radioactive in situ hybridization

In situ hybridization with the antisense probes against COX-1 and COX-2 showed a positive signal in some smooth muscle cell layers (COX-1, Fig. 4a, b), the interstitial gland cells and the granulosa layers (COX-2, Fig. 4c-f), respectively. The incubations with the according sense probes showed only very weak reaction. This con-

firmed the immunocytochemical results showing that the cyclooxygenases are synthesized in these locations.

Discussion

Prostaglandins (PGs) were first discovered in male accessory sex glands (von Euler, 1936) and later identified in the ovaries of several avian species (Bahr, 1990). It has been hypothesized that they may play an important role in female reproduction (Eliasson, 1959). Recent data have shown that PGs are associated with ovulation, ovum transport through the oviduct, in oviposition, and in induction of the sperm storage tubule opening through vaginal contractions (Sasanami et al., 2015). It has also been shown that the ability of PGs to stimulate oviductal contractions varies regionally along the oviduct.

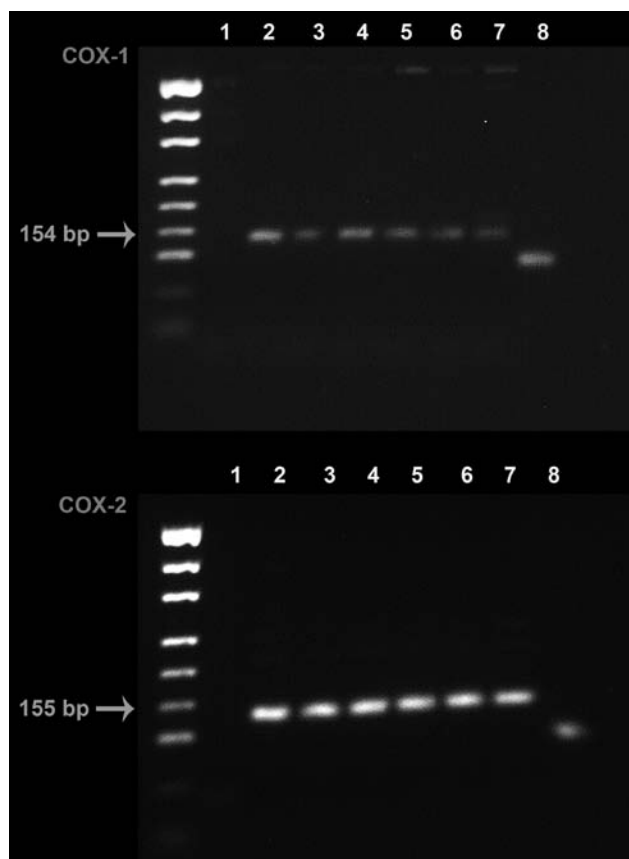


Fig. 3. RT-PCR

Running of the amplicons in 1.5 % agarose gel stained with Gel-Red. Distinct bands indicating the expression of COX-1 (154 bp) as well as COX-2 (155 bp) could be demonstrated in both large (lane 2, 3, 4) and small (lane 5, 6, 7) yellow follicles; lane 1: water; lane 8: β -actin (bp).

COX is regarded as the major enzyme that catalyses conversion of arachidonic acids to PG and other eicosanoids (Kirschenbaum et al., 2000). In birds, so far two isoforms of COX have been identified, COX-1, which has been reported to be constitutively expressed in several tissues and is required for various homeostatic functions (Smith et al., 2000), and COX-2, which is regarded to be inducible by various factors, including steroid hormones, cytokines and growth factors (Hales et al., 2008). The results obtained in our study do not support the generally accepted dichotomy of cyclooxygenase isoenzymes in a constitutively expressed (COX-1) and an induced isoform (COX-2). Both enzymes showed characteristic but different expression.

COX-1 appears nearly exclusively localized to the cytoplasm of perilacunar and stromal smooth muscle cells. Van Nassauw et al. (1992) have observed that even the isolated ovary of chicken is able to contract due to this network of muscle cells, and Guzsal (1966) suggests that smooth muscle contractions in the mature follicle is partly responsible for rupture of the stigma before ovulation. We believe that production of prostaglandins by COX-1 is probably important for the coordinated contractions of this intra-ovarian network of smooth muscle cells. Another outstanding feature of the

avian ovary, when compared with the mammalian ovary, is the large number of ganglion cells and the complex distribution of fine nerves (Gilbert, 1969). A lacunar system with smooth muscle cells in its wall, comparable to that found in the avian ovary, seems not to exist in the eutherian ovary (e.g. in the mouse, Callebaut, 1978). This could indicate that in the avian ovary, apart from controlling the blood flow and innervation of the thecal glands (Dahl, 1970), the neural supply may also have an influence on the coordinated contraction of the smooth muscle bands. Ovulation in birds involves a complex series of biochemical and biophysical processes that ultimately leads to the rupture of the vitellogenic preovulatory follicle and release of the megalecithal oocyte (Rodler and Sinowatz, 2015).

The process of ovulation shows all the signs of an acute, self-controlled inflammatory reaction, including hyperaemia, leucocyte extravasation, oedema, and induction of proteolytic activities (Espey, 1980; Espey and Lipner, 1994; Sirois et al., 2004). Prostaglandins, which are known to play an important role in inflammation, have been recognized as key mediators of ovulation in mammals for more than 30 years. COX-2 is induced by the preovulatory LH surge in the granulosa cell layer of the follicle prior to ovulation (Smith et al., 2000). Non-steroid anti-inflammatory drugs (NSAID) such as aspirin and indomethacin inhibit the ovulation in many mammalian species including rats, rabbits, pigs, sheep, cows and humans (Sirois et al., 2004). In these species, the LH surge causes a marked increase in the concentrations of PGE_2 and $\text{PGF}_{2\alpha}$ in ovarian follicles prior to ovulation, with granulosa cells as the primary sites of prostaglandin synthesis. Different mechanisms have been suggested as potential mechanisms responsible for the subsequent increase in follicular prostaglandins due to the LH surge (Sirois et al., 2004), including an increase in arachidonic acid release, induction of COX-2 expression in the granulosa cell layer of follicles and/or rise in prostaglandin synthase activity (Clark et al., 1978).

As in mammalian species, COX-2 is responsible for generation of PGE_2 in the preovulatory follicles that are destined to ovulate in the hen (Hales et al., 2008). However, a notable difference was found in the expression of COX-2 in the quail compared to the hen and the ostrich. In the hen, COX-2 was localized to the granulosa cell layer and cortical interstitium, ovarian surface epithelium, and postovulatory follicles and it was hypothesized that it may be involved in ovulation and oviposition (Hales et al., 2008). In the ostrich, COX-2 had its strongest expression in the granulosa layer cytoplasm of previtellogenic follicles and was very weak or nearly negative in vitellogenic follicles with a size > 1.8 cm. No immunostaining for COX-2 was found in preovulatory follicles. The involvement of prostaglandins derived from oocytes therefore appears unlikely. A completely different pattern of COX-2 immunostaining was found in the ovary of quails, where it was almost exclusively confined to the steroid hormone-producing cells of the interstitial gland cells. In quails, the interstitial/

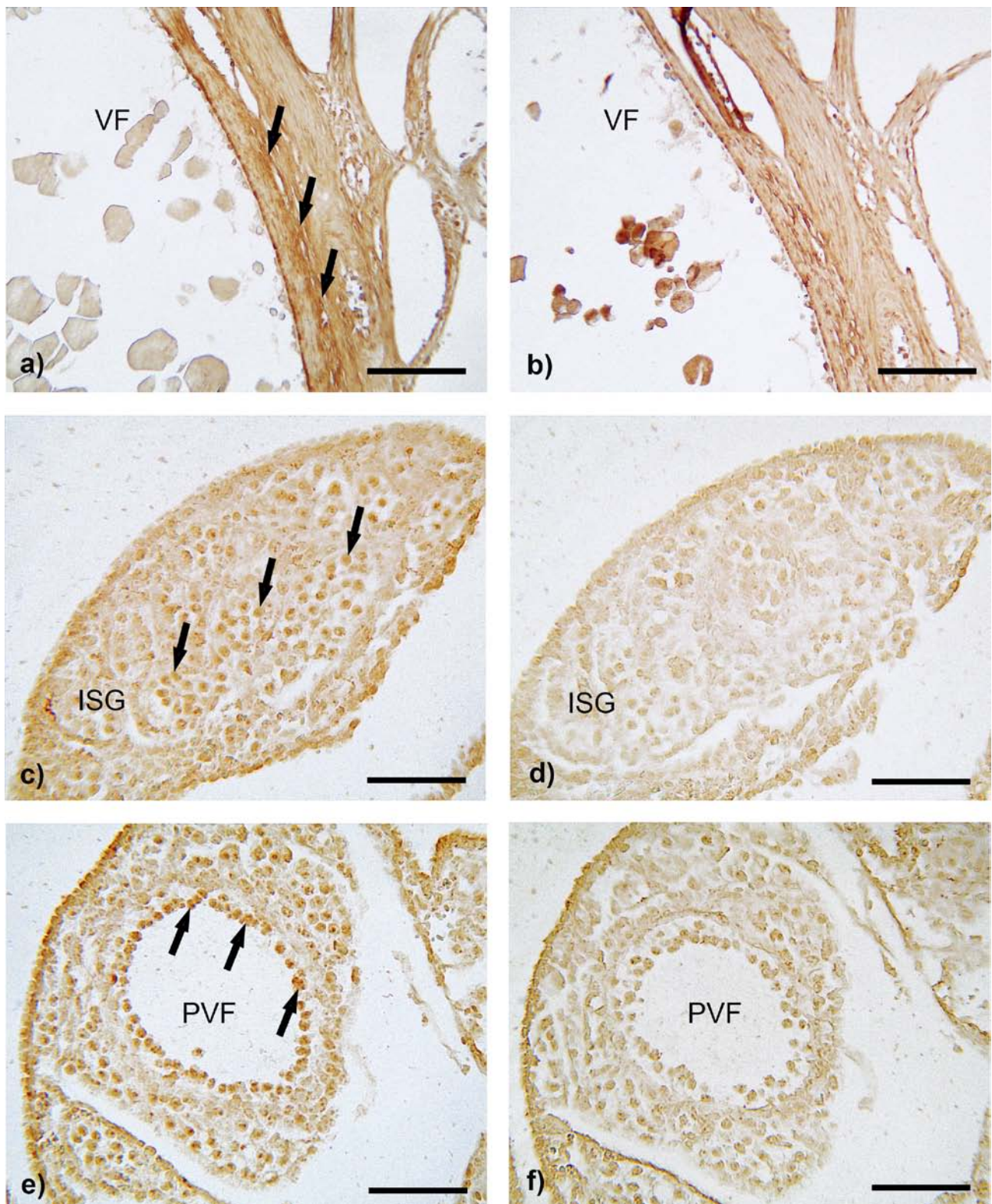


Fig. 4. In situ hybridization

a) COX-1, antisense probe: a distinct signal for COX-1 can be demonstrated in the smooth muscle cells (arrows) of the theca externa of this vitellogenic follicle (VF). **b)** COX-1, sense probe: no binding can be seen in the smooth muscle cells of the same follicle as in Fig. 3a. **c)** COX-2, antisense probe: within the interstitial gland cells (ISG), which are found throughout the ovary, mRNA for COX-2 can be demonstrated. **d)** COX-2, sense probe: the interstitial gland cells (ISG) at the same location as shown in Fig. 3c remain negative. **e)** COX-2, antisense probe: mRNA of COX-2 can be localized in the granulosa cells of follicle of all sizes (arrows), as demonstrated here for a previtellogenic follicle (PVF). **f)** COX-2, sense probe: the granulosa cells of the same follicle as in Fig. 3e give no signal.

Scale bars: **a, b** = 100 μ m; **c – f**: 40 μ m

thecal glands are islets of epithelial cells located mainly in the theca externa forming spherical or elongated gland clusters, usually two layers in thickness (Dahl, 1970). Two cell types can also be distinguished at the light microscopical level, the more centrally located steroid-producing cells and elongated cells, which are always found in the periphery of the gland. Whereas no immunostaining of any interstitial gland cell occurred with COX-1, distinct immunostaining of COX-2 was observed for the steroid hormone-producing cells. It has been well established that the inner polygonal cells have all the organelles required for steroid production, but our results for the first time show that the same cells are involved in prostaglandin synthesis. Johnson and Tilly (1990) have demonstrated that prostaglandins can attenuate LH-promoted progesterone production in the ovary of hens by inhibiting LH-induced cAMP production and by decreasing the ability of cells to convert cholesterol to pregnenolone.

Our results clearly demonstrate that both steroid hormone production and prostaglandin synthesis occur in the same cell type of the interstitial glands and it would be interesting to study the interactions between both pathways in more detail using biochemical and molecular biological techniques.

Acknowledgements

The authors gratefully acknowledge the technical assistance of Mrs Monica Settles, Mrs Angela Servatius, Mr Yilmaz Göck, and Mr Hans Kelm. The authors are also grateful to the Institute of Veterinary Nutrition, Department of Veterinary Sciences, Ludwig-Maximilians University Munich, Germany, for their generosity in providing ovaries of Japanese quails for this study.

References

- Bahr, J. (1990) The avian ovary. Model for endocrine studies. *J. Exp. Zool.* **4**, 192-194.
- Callebaut, M. (1978) Effects of centrifugation of living oocytes from adult Japanese quails. *Anat. Embryol.* **153**, 105-113.
- Clark, M. R., Marsh, J. M., LeMaire, W. J. (1978) Mechanisms of luteinizing hormone regulation of prostaglandin synthesis in rat granulosa cells. *J. Biol. Chem.* **253**, 7757-7761.
- Coleman, R. A., Smith, W. L., Narumiya, S. (1994) International Union of Pharmacology classification of prostanoid receptors: properties, distribution, and structure of the receptors and their subtypes. *Pharmacol. Rev.* **46**, 205-229.
- Dahl, E. (1970) Studies of the fine structure of ovarian interstitial tissue. 2. The ultrastructure of the thecal gland of the domestic fowl. *Z. Zellforsch.* **109**, 195-211.
- Eliasson, R. (1959) Studies on the prostaglandin occurrence, formation and biological actions. *Acta Physiol. Scand.* **158(Suppl)**, 1-73.
- Espey, L. L. (1980) Ovulation as an inflammatory response – a hypothesis. *Biol. Reprod.* **22**, 73-106.
- Espey, L. L., Lipner, H. (1994) Ovulation. In: *Physiology of Reproduction*, eds. Knobil, E., Neil, J. D., pp. 725-781, Raven Press, New York.
- Gilbert, A. B. (1969) Female genital organs. In: *Form and Function in Birds*, eds. King, A. S., McLelland, J., Vol. 1, Academic 1969, London.
- Guzsal, E. (1966) Histological studies on the mature and post-ovulation ovarian follicle of fowl. *Acta. Vet. Acad. Sci. Hung.* **16**, 37-44.
- Hales, D. B., Zunge, Y., Lagman, J. A., Ansenberger, K., Mahon, C., Barua, A., Luborsky, J. L., Bahr, J. M. (2008) Cyclooxygenase expression and distribution in the normal ovary and their role in ovarian cancer in the domestic hen (*Gallus domesticus*). *Endocrine* **33**, 235-244.
- Hsu, S. M., Raine, I., Fanger, H. (1981) Use of avidin-biotin-peroxidase complex (ABC) in immunoperoxidase techniques: a comparison between ABC and unlabelled antibody (PAP) procedure. *J. Histochem. Cytochem.* **29**, 577-580.
- Johnson, A. L., Tilly, J. L. (1990) Arachidonic acid inhibits luteinizing hormone-stimulated progesterone production in hen granulosa cells. *Biol. Reprod.* **42**, 458-554.
- Kirschenbaum, A., Liotta, D. R., Yao, S., Liu, X., Klausner, A. P., Unger, P., Shapiro, E., Leav, I., Levine, A. C. (2000) Immunohistochemical localization of cyclooxygenase-1 and cyclooxygenase-2 in the human fetal and adult male reproductive tracts. *J. Clin. Endocrinol. Metab.* **85**, 3436-3441.
- Narumiya, S., Sugimoto, Y., Ushikubi, F. (1999) Prostanoid receptors: structures, properties, and functions. *Physiol. Rev.* **79**, 1193-1226.
- Rodler, D., Sinowatz, F. (2015) Expression of prostaglandin synthesizing enzymes (cyclooxygenase 1 and cyclooxygenase 2) in the ovary of the ostrich (*Struthio camelus*). *Acta Histochem.* **117**, 69-75.
- Romeis, B. (2004) Färbemethoden. In: *Romeis – Mikroskopische Technik*, eds. Mulisch, M., Welsch, U., pp. 198-281, Springer Spectrum, Berlin. 2004.
- Sasanami, T., Shunsuke, I., Naoki, S., Toshifumi, H., Shusei, M., Mei, M., Gen, H., Eriko, Y., Takashi, Y., Kazuyoshi, U., Kazuyoshi, T. (2015) A unique mechanism of successful fertilization in a domestic bird. *Sci. Rep.* **5**, 7700.
- Sirois, J., Richards, J. S. (1993) Transcriptional regulation of the rat prostaglandin endoperoxide synthase 2 gene in granulosa cells. Evidence for the role of a cis-acting C/EBP β promoter element. *J. Biol. Chem.* **268**, 2131-2138.
- Sirois, J., Sayasith, K., Brown, K. A., Stock, A. E., Bouchard, N., Dore, M. (2004) Cyclooxygenase-2 and its role in ovulation: a 2004 account. *Hum. Reprod. Update* **10**, 375-385.
- Smith, W. L., Witt, D. L., Garavito, R. M. (2000) Cyclooxygenase: structural, cellular and molecular biology. *Annu. Rev. Biochem.* **69**, 145-182.
- Song, J. H., Sirois, J., Houde, A., Murphy, B. D. (1998) Cloning, developmental expression and immunohistochemistry of cyclooxygenase 2 in the endometrium during embryo implantation and gestation in mink (*Musculus vison*). *Endocrinology* **140**, 2685-2695.
- Van Nassauw, L., Callebaut, M., Harrisson, F., Scheuermann, D. W. (1992) Smooth muscle cells in the walls of ovarian follicles in the Japanese quail. *Cell Tissue Res.* **269**, 49-56.
- von Euler, U. S. (1936) On the specific vaso-dilatating and plain muscle stimulating substances from accessory genital glands in man and certain animals (prostaglandin and vesiglandin). *J. Physiol.* **88**, 213-234.