

Metronidazole Attenuates the Intensity of Inflammation in Experimental Autoimmune Uveitis

(experimental autoimmune uveitis / uveitis / antibiotics / microbiome / metronidazole / ciprofloxacin)

P. SEIDLER STANGOVA¹, O. DUSEK¹, A. KLIMOVA¹, J. HEISSIGEROVA¹,
T. KUCERA², P. SVOZILKOVA¹

¹Department of Ophthalmology, First Faculty of Medicine, Charles University and General University Hospital in Prague, Prague, Czech Republic

²Institute of Histology and Embryology, First Faculty of Medicine, Charles University, Prague, Czech Republic

Abstract. Autoimmune uveitis is a serious sight-threatening disease that in many cases fails to respond to conventional immunosuppressive or biological therapy. Experimental models used in research allow more detailed study of pathogenesis of the autoimmune process and testing new therapeutic strategies. Recent results show that infection can trigger autoimmune diseases, and some commensal microorganisms are essential in causing disease activity. The aim of this work was to assess the effect of broad-spectrum antibiotics – combination of metronidazole and ciprofloxacin or metronidazole alone – on the intensity of intraocular inflammation in experimental autoimmune uveitis (EAU). EAU was induced in mouse strain C57BL/6J by interphotoreceptor retinoid-binding protein in complete Freund's adjuvant and pertussis toxin. The grade of uveitis was assessed clinically and histologically in haematoxylin and eosin-stained tissues. Lymphocytes and macrophages were detected in cryosections using the immunoperoxidase method with antibodies. The therapy was commenced one week before EAU induction and continued throughout the experiment. In addition,

metronidazole treatment was also started two weeks before EAU induction. Antibiotics significantly reduced the intensity of uveitis compared to the control group ($P < 0.05$). The effects of combination of ciprofloxacin and metronidazole and of metronidazole alone were similar when the therapy started one week before EAU induction ($P < 0.05$). Metronidazole commenced two weeks before EAU induction and throughout the experiment suppressed the intensity of EAU with even higher statistical significance ($P < 0.0001$). It can be assumed that the high protective effect of metronidazole on EAU intensity may be due not only to its antimicrobial effect, but also to its immunomodulatory activity.

Introduction

Uveitis is a sight-threatening intraocular inflammation that mostly affects people of working age. The aetiology may be infectious or non-infectious – autoinflammatory or autoimmune (Forrester et al., 2018). In more than 25 % of these cases, uveitis is associated with systemic diseases such as sarcoidosis, multiple sclerosis, ankylosing spondylitis, juvenile idiopathic arthritis, Behcet's disease, etc. However, in many patients it is not possible to determine the aetiology, and thus 40–50 % of cases remain idiopathic (Rothova et al., 1992).

Despite expanding therapeutic possibilities, the clinical course of intraocular inflammation may be resistant to treatment and 10 % of patients become blind due to the complications of uveitis (Suttorp-Schulten et al., 1996; Durrani et al., 2004). The heterogeneity of the disease with a wide spectrum of clinical presentations is the major impediment for extensive clinical studies in human. Therefore, animal models of experimental autoimmune uveitis (EAU), which allow more detailed studies of pathogenesis of uveitis and testing new therapeutic strategies, have been developed (Caspi et al., 2008; Xu et al., 2008).

Received September 9, 2019. Accepted November 20, 2019.

This study was supported by the research project from the Ministry of Health of the Czech Republic AZV MZ CR 17-31248A and by Charles University Institutional Programme SVV 260367.

Corresponding author: Petra Svozilkova, Department of Ophthalmology, First Faculty of Medicine, Charles University and General University Hospital in Prague, U Nemocnice 2, 128 08 Prague 2, Czech Republic. E-mail: petra.svozilkova@lf1.cuni.cz

Abbreviations: CFA – complete Freund's adjuvant, DMSO – dimethyl sulphoxide, EAU – experimental autoimmune uveitis, IRBP – interphotoreceptor retinoid-binding protein, PBS – phosphate-buffered saline, PT – pertussis toxin, Tregs – regulatory T cells, HE – haematoxylin and eosin.

Among environmental factors and susceptibility genes involved in autoimmune diseases, the role of infectious pathogens has been considered to be crucial in the process of triggering the immunological response. Specific pathogens such as *Chlamydomphila* (*Chlamydia pneumoniae*), human herpes virus 6, and Epstein-Barr virus are implicated in either the development or progression of multiple sclerosis (Pawate and Sriram, 2010). For several rheumatoid diseases, infections by *Chlamydia*, *Shigella*, *Salmonella*, *Yersinia* or *Campylobacter* seem pathogenetically significant (Townes, 2010). In the process of autoimmune uveitis, the suspected pathogens have been *Helicobacter pylori*, *Yersinia* and *Salmonella* (Cancino-Diaz et al., 2004; Otasevic et al., 2007; Galeone et al., 2012). Research in the experimental models of spontaneously developing intestinal inflammation suggests that innate immunity, mucosal barrier defects or disruption of T lymphocyte regulatory functions could lead to chronic intestinal inflammation. Interestingly, the disease can be prevented when mice are kept in germ-free conditions in contrast to conventionally housed mice (Sellon et al., 1998; Hudcovic et al., 2001; Hrnčir et al., 2008; Stehlikova et al., 2019). Similar results were shown by studies performed in other autoimmune experimental models, for example rheumatoid arthritis (Tlaskalova-Hogenova et al., 2004; Scher and Abramson, 2011), inflammatory bowel disease (Tlaskalova-Hogenova et al., 2004; Biswas et al., 2011), type 1 diabetes mellitus (Tlaskalova-Hogenova et al., 2004; Wen et al., 2008; Sorini et al. 2019), celiac disease (Tlaskalova-Hogenova et al., 2004), multiple sclerosis (Tlaskalova-Hogenova et al., 2004, Pawate and Sriram, 2010), and psoriasis (Zakostelska et al., 2016; Stehlikova et al., 2019). Dysregulation in the microbiome can induce a severe immune response as well as immune-mediated intraocular inflammation (Heissigerova et al., 2016; Nakamura et al., 2016; Horai and Caspi, 2019).

Current knowledge shows that commensal microorganisms affect many aspects of immune system maturation and homeostasis in health and disease. Increasing evidence suggests that the gut commensals affect not only intestinal diseases, but also diseases of tissues and organs distant from the gut. Microbiota may also serve as an “adjuvant” providing innate signals that amplify and direct the host immune response for development of uveitis (Horai and Caspi, 2019). It is therefore reasonable to assume that influencing the microbiome by antibiotic treatment could be effective in many autoimmune diseases. Nakamura et al. (2016) reported that oral but not intraperitoneal broad-spectrum antibiotics (ampicillin, metronidazole, neomycin, and vancomycin) administered simultaneously one week prior to EAU induction increased regulatory T cells (Tregs) in the intestinal lamina propria and extraintestinal lymphoid tissues in EAU animals. Vancomycin or metronidazole given for one week before immunization decreased the intensity of uveitis, whereas neither neomycin nor ampicillin significantly altered the uveitis score in B10.RIII mice.

On the other hand, some commensal microbiota have a protective effect against development of autoimmune diseases. Therefore, probiotics have been recognized to have a beneficial effect in the treatment of a variety of inflammatory diseases, for instance type 1 diabetes, multiple sclerosis, rheumatoid arthritis, and inflammatory bowel disease (Gardlik et al., 2012; Kim et al., 2017; Liu et al. 2018; Sales-Campos et al., 2019). It has been demonstrated that commensal intestinal bacterial metabolites short chain fatty acids increase prevalence of Tregs in the gut (Smith et al., 2013) and can be utilized to suppress autoimmune uveitis (Lin, 2019).

As we have shown previously that a combination of metronidazole and ciprofloxacin suppresses the intensity of EAU in mouse strain C57BL/6J (Heissigerova et al., 2016), we wanted to explore whether the same effect would be obtained with metronidazole alone.

Ciprofloxacin is a second-generation fluoroquinolone, with a broad spectrum of activity, which includes many Gram-negative and Gram-positive bacterial pathogens (Sarker et al., 2014). Metronidazole (nitroimidazole) is one of the rare examples of a drug developed against protozoans (*Entamoeba histolytica*, *Giardia lamblia* and *Trichomonas vaginalis*), which has since gained broad use as an antibacterial agent against some Gram-negative (*Bacteroides* and *Fusobacterium* spp.) and Gram-positive anaerobic bacteria (*Peptostreptococcus* spp. and *Clostridia* spp.) (Grove et al., 1977). Moreover, the immunomodulatory effect of metronidazole has been demonstrated in recent studies (Rizzo et al., 2010; Becker et al., 2016).

Material and Methods

Animals

Inbred female mice of the C57BL/6J strain (5 to 8 weeks old) were obtained from the animal facility of the Centre of Experimental Biomodels, First Faculty of Medicine, Charles University, Prague. Mice were housed at the conventional animal facility of the Institute of Pharmacology, First Faculty of Medicine, Charles University, Prague. The use of animals for these experiments was approved by the Commission for Animal Welfare of the First Faculty of Medicine, Charles University, Prague, Czech Republic, and the Ministry of Education, Youth and Sports according to animal protection laws. All the procedures were approved by the animal experimentation review committee.

EAU induction

EAU was induced by subcutaneous inoculation of interphotoreceptor retinoid-binding protein (IRBP) 500 µg per mouse in complete Freund's adjuvant (CFA) in conjunction with intraperitoneal application of pertussis toxin (PT) 1.2 µg according to a standard protocol (Avichezer et al., 2000; Broderick et al., 2002). In brief, IRBP 1-20 (H2N-GPTHFLFQPSLVLDMAKVVLLD-OH, New England Peptide, Gardner, MA) dissolved in dime-

thyl sulphoxide (DMSO) (Sigma-Aldrich, St. Louis, MO) was emulsified in ratio 1 : 1 with CFA (Difco, Detroit, MI) and the solution was applied subcutaneously.

Antibiotic treatment

In this study, two treatment groups and one control group were used. In the treatment arm, one group of mice was treated with a mixture of broad-spectrum antibiotics – ciprofloxacin 100 mg/l (Ciprinol, Krka Č. R., Prague, Czech Republic) and metronidazole 500 mg/l (B. Braun, Prague, Czech Republic); the second group of mice was treated with monotherapy using metronidazole 500 mg/l. Antibiotics were dissolved in drinking water and changed every three days to maintain the effectiveness as previously described (Klimesova et al., 2013; Zakostelska et al., 2016). Treatment was initiated one week prior to EAU induction and continued until the end of the experiment. In addition, monotherapy using metronidazole was also commenced two weeks prior to EAU induction to establish the importance of microbiota with respect to the disease induction.

Clinical evaluation

In vivo clinical examination (bio-microscopy) was performed using a special endoscopic imaging system (Paques et al., 2007; Copland et al., 2008; Xu et al., 2008). An additional +4.0 dioptre lens between the camera and the otoscope was used. During the procedure, the mice were under intraperitoneal general anaesthesia (ketamine 80 mg/kg and xylazine 5 mg/kg; both Bioveta, Nitra, Slovakia). The fundi were imaged through a dilated pupil using tropicamide (Unitropic 1% oph. gtt., Unimed Pharma, Bratislava, Slovakia) and phenylephrine (Neosynephrin-POS 10% oph. gtt., URSAPHARM, Prague, Czech Republic). The otoscope was applied to the cornea covered with eye gel carbomerum (Vidisic gel, Bausch and Lomb, Prague, Czech Republic). A single image of the posterior central fundus from each eye was taken and transferred to a computer for analysis.

The inflammation was graded as described previously (Xu et al., 2008; Heissigerova et al., 2016). Retinal inflammatory changes were evaluated separately for the optic disc, retinal vessels, and retinal tissue changes from the central fundus. The overall clinical inflammation grade was then averaged. All samples were evaluated by two experienced ophthalmologists on days 21 and 28 after EAU induction and the discussed consensus of the two evaluations was used.

Histological evaluation

The mice were sacrificed on day 35 after the EAU induction and the eyes were enucleated and immediately immersed in Tissue-Tek® O.C.T. Compound™ (Sakura Finetek, Inc., Torrance, CA) and frozen in 2-methylbutane (Sigma-Aldrich, St. Louis, MO) in liquid nitrogen. The samples were stored at -70°C until sectioning to 7 μm thick slices (at -19 to -21°C). Sections were taken from both eye peripheries and centrally through the optic nerve. The samples were cut with a

cryostat (Leica CM 1850, Leica Microsystems Nussloch GmbH, Nussloch, Germany) and stained with haematoxylin and eosin. These samples were then evaluated by two experienced ophthalmologists and graded using a standardized scoring system as previously published (Dick et al., 1994; Thurau et al., 1997; Caspi, et al., 2008; Klimova et al., 2014; Heissigerova et al., 2016). Eyes with congenital defects, such as microphthalmia or cataract, have been excluded from evaluation, which led to odd numbers in some graphs.

Immunohistochemistry

The immunohistochemistry was performed on three randomly selected mice from each group. T-lymphocytes were detected using a three-step immunoperoxidase method with polyclonal rabbit anti-human CD3 (Dako Denmark A/S, Glostrup, Denmark) diluted 1 : 200 in PBS containing 1.5% normal goat serum. This antibody is cross-reactive with mouse antigens (Jones et al., 1993). Visualization of primary antibody binding was performed using secondary biotinylated anti-rabbit antibody (Dako) and the VECTASTAIN Elite ABC kit standard (Vector Laboratories, Burlingame, CA). Macrophages were detected using a three-step immunoperoxidase method with monoclonal rat anti-mouse F4/80 antibody (clone BM8, Abcam, Cambridge, UK) diluted 1 : 100 in PBS containing 1.5% normal goat serum. Visualization of primary antibody binding was performed using secondary biotinylated anti-rat antibody (Abcam) and the VECTASTAIN Elite ABC kit standard (Vector Laboratories). Positive cells were counted in two sections per eye, one from the periphery and one from the centre, to obtain quantitative data.

Data analysis

Data were analysed using GraphPad Prism Version 8.01 for Windows (GraphPad Software, San Diego, CA, <http://www.graphpad.com/>). Kruskal-Wallis and Mann-Whitney nonparametric tests were used to evaluate differences between the groups. The P value of < 0.05 was considered significant.

Results

Clinical, histological and immunohistochemical evaluation of the dynamics of inflammatory intensity in EAU

Our previous unpublished data showed that the intensity of intraocular inflammation in the mouse model was strongest between days 25 and 35 after EAU induction (Fig. 1).

Until day 20, no or only minimal clinical signs of uveitis could be observed. Maximal clinical activity was observed between days 25 and 28 after EAU induction, whereas histological evaluation showed the strongest inflammatory changes on the 35th day. The discrepancy can be explained by the limited number of the eye sections that were stained and evaluated. On the contrary,

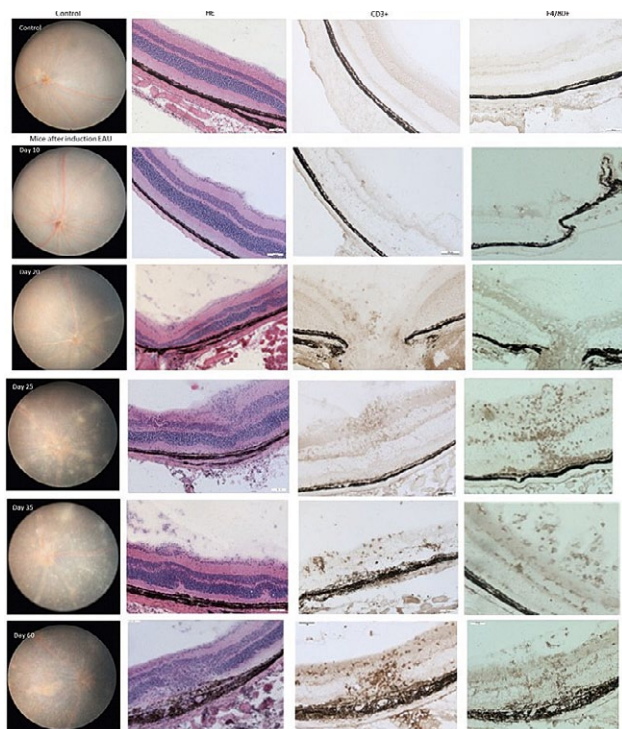


Fig. 1. Dynamics of changes in mice after induction of EAU

Dynamics of changes on days 10, 20, 25, 35, and 60 after EAU induction documented by clinical, histological (haematoxylin and eosin) and immunohistochemical evaluation of T cells (CD3⁺) and macrophages (F4/80⁺). Mild activity of uveitis was documented on day 20, maximum of inflammatory activity was seen between days 25 and 35. On day 60, atrophic changes of the retina were apparent.

during the clinical examination it is possible to examine the entire retina. After day 20, an increased number of T lymphocytes and macrophages was observed. Between days 25–35, the numbers of these immune cells were constant. On day 60, atrophic changes of the retina were apparent.

According to our findings, the following design of experiments with antibiotic treatment was proposed – clinical evaluation on days 21 and 28; histological and immunohistochemical evaluation on day 35 after EAU induction. Untreated mice were compared with mice treated with a mixture of broad-spectrum antibiotics – ciprofloxacin and metronidazole – or with metronidazole alone.

The intensity of inflammation was attenuated in mice treated with a combination of metronidazole and ciprofloxacin or metronidazole alone started one week before EAU induction

The intensity of inflammation in EAU was significantly reduced in mice treated with a mixture of antibiotics ciprofloxacin and metronidazole or metronidazole alone compared to the control group. The therapy

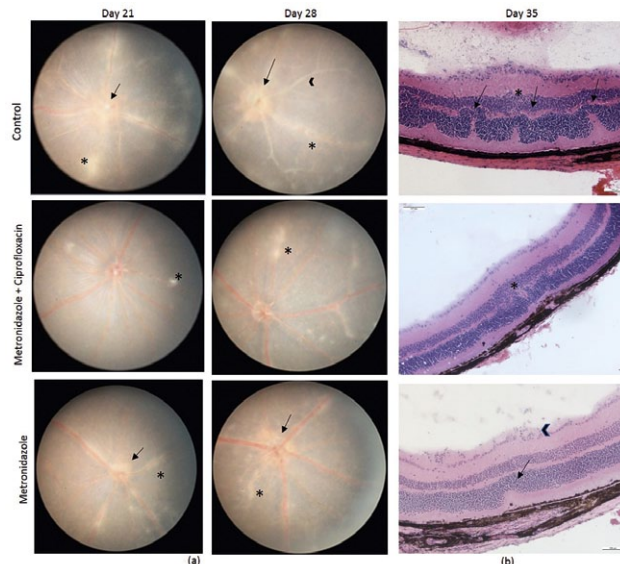


Fig. 2. Clinical and histological examination in mice treated with antibiotics one week before EAU induction

(a) Clinical examination on the 21st and 28th day after induction of EAU in control mice and mice treated with antibiotics (combination of metronidazole and ciprofloxacin or metronidazole alone). Treatment started one week before EAU induction. Retinal changes in control mice show several linear lesions (star), swelling of optic disc (arrow), and moderate vascular cuffing (arrowhead). In mice treated with antibiotics, small lesions, mild inflammation of optic disc (arrow) and engorged vessels (arrowhead) are seen.

(b) Histological examination of haematoxylin and eosin-stained retina of control and antibiotic-treated mice on day 35 after EAU induction. Histological image of control mice showing grade 3: severe vasculitis (arrowhead), mild vitritis, several retinal folds (arrows), granuloma (star). In mice treated with the combination of antibiotics, EAU of grade 1 was observed, in mice treated with metronidazole, grade 2 was observed.

started one week before EAU induction and continued throughout the experiment.

By clinical evaluation, lower intensity of inflammation was observed in mice treated with a combination of metronidazole and ciprofloxacin on the 21st day and 28th day after EAU induction (Fig. 2a; Fig. 4a; $P < 0.0001$ on day 21 and $P = 0.0061$ on day 28). In mice treated with metronidazole alone, attenuation of the inflammatory activity was also demonstrated on the 21st day and 28th day after induction (Fig. 2a; Fig. 4a; $P = 0.0027$ on day 21 and $P = 0.0085$ on day 28).

By histological evaluation, only mild signs of uveitis were observed in mice treated with a combination of antibiotics ciprofloxacin and metronidazole on the 35th day compared to severe inflammation in control mice (Fig. 2b; Fig. 4b; $P = 0.0027$). In mice treated with metronidazole alone, a significant decrease of inflammation was also confirmed (Fig. 2b; Fig. 4b; $P = 0.0124$).

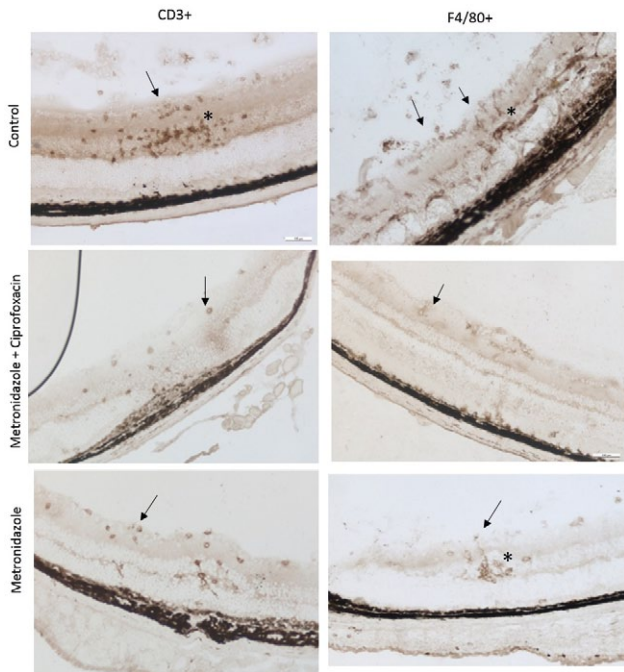


Fig. 3. Immunohistochemistry of the eyes in mice treated with antibiotics one week before EAU induction. Immunohistochemistry on day 35 after induction of EAU showed reduction of both CD3⁺ T cells and F4/80⁺ macrophages in mice treated with antibiotics compared to the controls. In control mice, CD3⁺ cells (T lymphocytes) and F4/80⁺ cells (macrophages) were present in the vitreous and concentrated as clumps in granulomas (stars) and as single cells in the inner and outer retinal layers (arrows). In mice treated with antibiotics, single cells were distributed in the inner retinal layers (arrows).

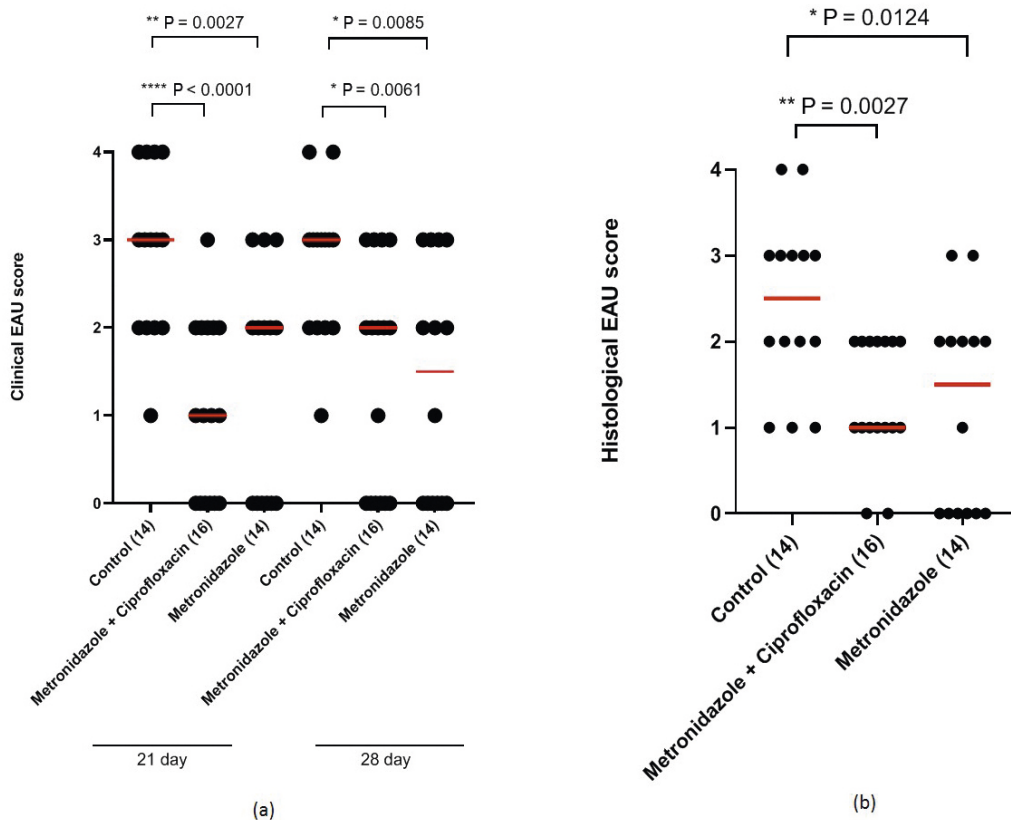


Fig. 4. Reduced severity of EAU in mice treated with antibiotics one week before EAU induction. (a) Quantification of clinical EAU score is shown. Red lines in the graphs represent the mean. *P < 0.05 (Mann-Whitney test). Mice treated with a combination of metronidazole and ciprofloxacin (16 eyes) showed reduced severity of EAU; P < 0.0001 on day 21 and P = 0.0061 on day 28. In mice treated with metronidazole alone (14 eyes), attenuation of inflammatory activity was also demonstrated on the 21st day and 28th day after induction; P = 0.0027 on day 21 and P = 0.0085 on day 28. (b) Quantification of histological EAU score is shown. Red lines in the graphs represent the mean. *P < 0.05 (Mann-Whitney test). Mice treated with the combination of antibiotics showed attenuation of inflammatory activity (P = 0.0027). In mice treated with metronidazole alone, a significant decrease of inflammation was also confirmed (P = 0.0124).

The intensity of inflammation was attenuated in mice treated with metronidazole started two weeks before EAU induction

In comparison with the control group, the intensity of inflammation was significantly attenuated in mice treated with metronidazole commenced two weeks before EAU induction; the therapy continued throughout the experiment.

By clinical funduscopy, no inflammation was observed on the 21st day and 28th day after EAU induction (Fig. 5a; Fig. 7a; $P < 0.0001$ on day 21 and $P = 0.0110$ on day 28). By histological evaluation, no or only minimal signs of uveitis were observed on the 35th day (Fig. 5b; Fig. 7b; $P < 0.0001$).

Immunohistochemistry of the eyes

Immunohistochemical evaluation of the eyes performed on day 35 showed reduction in both CD3⁺ T cells (29% decrease in the group with a combination of antibiotics and 11% decrease in the group with metronidazole alone) and F4/80⁺ macrophages (39% decrease in the group with a combination of antibiotics and 35% decrease in the group with metronidazole alone) in mice treated with antibiotics started one week before EAU induction compared to the controls (Fig. 3; Fig. 6). In mice treated with metronidazole started two weeks before EAU induction (Fig. 6), the numbers of inflamma-

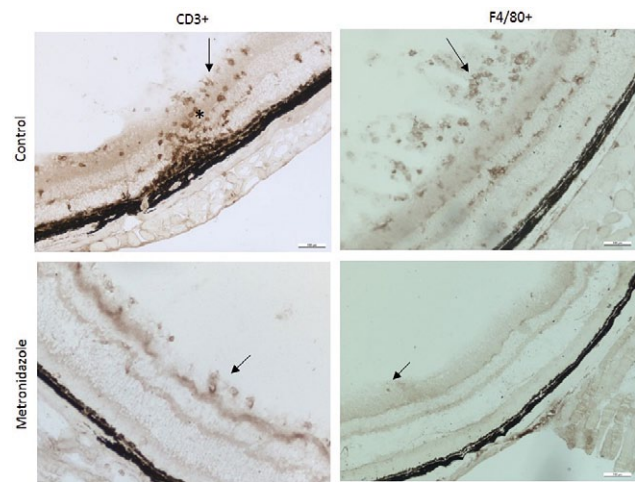


Fig. 6. Immunohistochemistry of the eyes of mice treated with metronidazole two weeks before induction of EAU. Immunohistochemistry of the eyes on day 35 after induction of EAU showed reduction of both CD3⁺ T cells and F4/80⁺ macrophages in mice treated with metronidazole compared to the controls.

In control mice, CD3⁺ cells (T lymphocytes) and F4/80⁺ cells (macrophages) were present in the vitreous and concentrated as clumps in granulomas (star) and as single cells in the inner and outer retinal layers (arrows). In mice treated with metronidazole, single cells were distributed in the inner retinal layers (arrows).

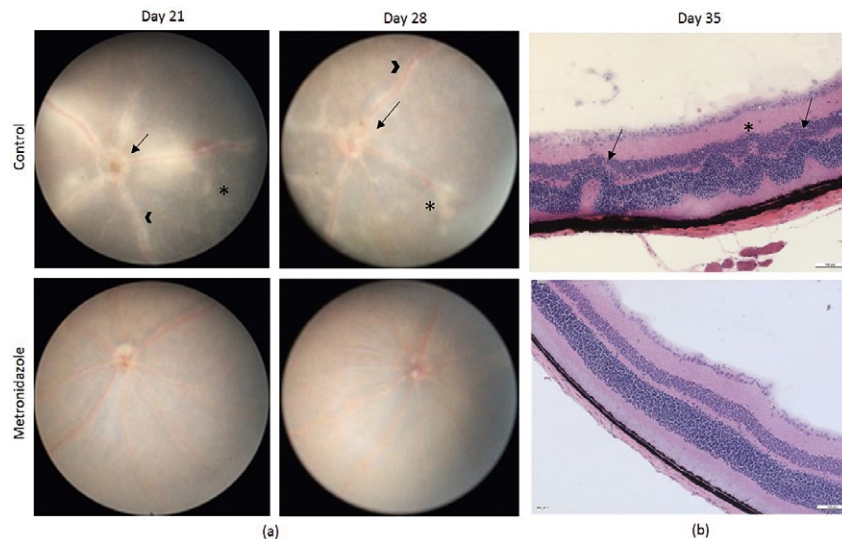


Fig. 5. Clinical and histological examination in mice treated with metronidazole two weeks before induction of EAU. (a) Clinical examination on days 21 and 28 after induction of EAU of control mice and mice treated with metronidazole. Retinal changes in control mice show several linear lesions (star), moderate inflammation of optic disc (arrow), and moderate vascular cuffings (arrowhead). In mice treated with metronidazole, normal fundus without pathological changes is seen.

(b) Histological examination of haematoxylin and eosin-stained retina of control mice and mice treated with metronidazole on day 35 after induction of EAU. Histological image of control mice shows grade 3 of EAU: severe vasculitis, mild vitritis, several retinal folds (arrows), granuloma (star). In mice treated with metronidazole, grade 0 is seen.

In our study, a more significant decrease in the intensity of uveitis was observed when metronidazole was commenced two weeks before EAU induction. A similar therapeutic benefit was reported in the study of Stehlikova et al. (2019), where oral treatment with broad-spectrum antibiotics or metronidazole alone mitigated the severity of skin inflammation in the experimental mouse model of psoriasis induced by imiquimod. Interestingly, metronidazole therapy did not decrease skin inflammation in the same model under germ-free conditions. This finding supports the conclusion that the therapeutic effect of metronidazole in autoimmune diseases is mediated by changes in the microbiota composition rather than by its immunosuppressive effect.

The relationship between the microbiota and uveitis is being intensively studied. However, the triggers of most types of uveitis are still unknown. Therefore, animal models are powerful tools to unravel the basic mechanisms of the disease (Horai and Caspi, 2011). Microbiota can have both a causal (Horai and Caspi, 2019) and a protective effect in immune-mediated uveitis (Lin, 2019). Our results support the current view that microbiota plays an important role in the pathogenesis of autoimmune uveitis and may lead to new potential targets for therapeutic modulation of the disease (Horai, 2017, Janowitz et al., 2019). However, it is still not fully understood how uveitis can be treated or prevented by modulating the intestinal microbiome. Further research addressing the mechanisms by which microbiota promotes the development of autoimmune diseases is essential for understanding the causal relationships between treating and attenuating the disease activity or preventing the disease induction.

Competing interests

The authors declare that there are no competing interests regarding the publication of this paper.

References

- Avichezer, D., Silver, P. B., Chan, C.-C., Wiggert, B., Caspi, R. R. (2000) Identification of a new epitope of human IRBP that induces autoimmune uveoretinitis in mice of the H-2b haplotype. *Invest. Ophthalmol. Vis. Sci.* **41**, 127-131.
- Bamias, G., Marini, M., Moskaluk, C. A., Odashima, M., Ross, W. G., Rivera-Nieves, J., Cominelli F. (2002) Down-regulation of intestinal lymphocyte activation and Th1 cytokine production by antibiotic therapy in a murine model of Crohn's disease. *J. Immunol.* **169**, 5308-5314.
- Becker, E., Bengs, S., Aluri, S., Opitz, L., Atrott, K., Stanzel, C., Castro, P. A. R., Rogler G., Frey-Wagner, I. (2016) Doxycycline, metronidazole and isotretinoin: do they modify microRNA/mRNA expression profiles and function in murine T-cells? *Sci. Rep.* **6**, 37082.
- Biswas, A., Wilmanski, J., Forsman, H., Hrcir, T., Hao, L., Tlaskalova-Hogenova, H., Kobayashi, K. S. (2011) Negative regulation of Toll-like receptor signaling plays an essential role in homeostasis of the intestine. *Eur. J. Immunol.* **41**, 182-194.
- Broderick, C., Hoek, R. M., Forrester, J. V., Liversidge, J., Sedgwick, J. D., Dick, A. D. (2002) Constitutive retinal CD200 expression regulates resident microglia and activation state of inflammatory cells during experimental autoimmune uveoretinitis. *Am. J. Pathol.* **161**, 1669-1677.
- Cancino-Diaz, J. C., Vargas-Rodríguez, L., Grinberg-Zylberbaum, N., Reyes-López, M. A., Domínguez-López, M. L., Pablo-Velazquez, A., Cancino-Diaz, M. E. (2004) High levels of IgG class antibodies to recombinant HSP60 kDa of *Yersinia enterocolitica* in sera of patients with uveitis. *Br. J. Ophthalmol.* **88**, 247-250.
- Caspi, R. R., Silver, P. B., Luger, D., Tang, J., Cortes, L.M., Pennesi, G., Mattapallil, M. J., Chan, C. C. (2008) Mouse models of experimental autoimmune uveitis. *Ophthalmic Res.* **40**, 169-174.
- Colpaert, S., Liu, Z., De Greef, B., Rutgeerts, P., Ceuppens, J. L., Geboes, K. (2001) Effects of anti-tumour necrosis factor, interleukin-10 and antibiotic therapy in the indometacin-induced bowel inflammation rat model. *Aliment. Pharmacol. Ther.* **15**, 1827-1836.
- Copland, D. A., Wertheim, M. S., Armitage, W. J., Nicholson, L. B., Raveney, B. J. E., Dick, A. D. (2008) The clinical time-course of experimental autoimmune uveoretinitis using topical endoscopic fundal imaging with histologic and cellular infiltrate correlation. *Invest. Ophthalmol. Vis. Sci.* **49**, 5458-5465.
- Dick, A. D., Cheng, Y. F., Liversidge, J., Forrester, J. V. (1994) Immunomodulation of experimental autoimmune uveoretinitis: a model of tolerance induction with retinal antigens. *Eye* **8**, 52-59.
- Durrani, O. M., Tehrani, N. N., Marr, J. E., Moradi, P., Stavrou, P., Murray, P. I. (2004) Degree, duration, and causes of visual loss in uveitis. *Br. J. Ophthalmol.* **88**, 1159-1162.
- Fararjeh, M., Mohammad, M. K., Bustanji, Y., Alkhatib, H., Abdalla, S. (2008) Evaluation of immunosuppression induced by metronidazole in Balb/c mice and human peripheral blood lymphocytes. *Int. Immunopharmacol.* **8**, 341-350.
- Forrester, J. V., Kuffova, L., Dick, A. (2018) Autoimmunity, autoinflammation, and infection in uveitis. *Am. J. Ophthalmol.* **189**, 77-85.
- Galeone, M., Colucci, R., D'Erme, A. M., Moretti, S., Lotti, T. (2012) Potential infectious etiology of Behçet's disease. *Patholog. Res. Int.* **2012**, 595380.
- Gardlik, R., Palffy, R., Celec, P. (2012) Recombinant probiotic therapy in experimental colitis in mice. *Folia Biol. (Praha)* **58**, 238-245.
- Grove, I., Mahmoud, A. A. F., Warren, K. S. (1977) Suppression of cell-mediated immunity by metronidazole. *Int. Arch. Allergy Appl. Immunol.* **54**, 422-427.
- Heissigerova, J., Seidler Stangova, P., Klimova, A., Svozilkova, P., Hrcir, T., Stepankova, R., Kverka, M., Tlaskalova-Hogenova, H., Forrester, J. V. (2016) The microbiota determines susceptibility to experimental autoimmune uveoretinitis. *J. Immunol. Res.* **2016**, 5065703.
- Horai, R., Caspi, R. R. (2011) Cytokines in autoimmune uveitis. *J. Interferon Cytokine Res.* **31**, 733-744.
- Horai, R. (2017) Gut microbiota linked to autoimmune uveitis. *Ann. Eye Sci.* **2**, 19.
- Horai, R., Caspi, R. R. (2019) Microbiome and autoimmune uveitis. *Front. Immunol.* **10**, 32.

- Hrnčir, T., Stepankova, R., Kozakova, H., Hudkovic, T., Tlaskalova-Hogenova, H. (2008) Gut microbiota and liposaccharide content of the diet influence development of regulatory T cells: studies in germ-free mice. *BMC Immunol.* **9**, 65.
- Hudkovic, T., Stepankova, R., Cebra, J., Tlaskalova-Hogenova, H. (2001) The role of microflora in the development of intestinal inflammation: acute and chronic colitis induced by dextran sulfate in germ-free and conventionally reared immunocompetent and immunodeficient mice. *Folia Microbiol. (Praha)* **246**, 565-572.
- Janowitz, C., Nakamura, Y. K., Metea, C., Gligor, A., Yu, W., Karstens, L., Rosenbaum, J. T., Asquith, M., Lin, P. (2019) Disruption of intestinal homeostasis and intestinal microbiota during experimental autoimmune uveitis. *Invest. Ophthalmol. Vis. Sci.* **60**, 420-429.
- Jones, M., Cordell, J. L., Beyers, A. D., Tse, A. G., Mason, D. Y. (1993) Detection of T and B cells in many animal species using cross-reactive anti-peptide antibodies. *J. Immunol.* **150**, 5429-5435.
- Khan, K. J., Ullman, T. A., Ford, A. C., Abreu, M. T., Marshall, J. K., Talley, N. J., Moayyedi, P. (2011) Antibiotic therapy in inflammatory bowel disease: a systematic review and meta-analysis. *Am. J. Gastroenterol.* **106**, 661-673.
- Kim, J., Choi, S. H., Kim, Y. J., Jeong, H. J., Ryu, J. S., Lee, H. J., Kim, T. W., Im, S. H., Oh, J. Y., Kim, M. K. (2017) Clinical effect of IRT-5 probiotics on immune modulation of autoimmunity or alloimmunity in the eye. *Nutrients* **9**, 11.
- Klimesova, K., Kverka, M., Zakostelska, Z., Hudkovic, T., Hrnčir, T., Stepankova, R., Rossmann, P., Ridl, J., Kostovcik, M., Mrazek, J., Kopečný, J., Kobayashi, K. S., Tlaskalova-Hogenova, H. (2013) Altered gut microbiota promotes colitis-associated cancer in IL-1 receptor-associated kinase M-deficient mice. *Inflamm. Bowel Dis.* **19**, 1266-1277.
- Klímová, A., Seidler Štangová, P., Heissigerová, J., Svozilková, P., Kučera, T. (2014) Mycophenolate mofetil and cyclophosphamide treatments suppress inflammation intensity in an experimental model of autoimmune uveitis. *Folia Biol. (Praha)* **60**, 228-234.
- Lin, P. (2019) Importance of the intestinal microbiota in ocular inflammatory diseases. *Clin. Exp. Ophthalmol.* **47**, 418-422.
- Liu, Y., Allokaran, J. J., Rhoads, J. M. (2018) Probiotics in autoimmune and inflammatory disorders. *Nutrients* **10**, 10.
- Nakamura, Y. K., Metea, Ch., Karstens, L., Asquith, M., Gruner, H., Moscibrocki, C., Lee, I., Brislawn, C. J., Jansson, J. K., Rosenbaum, J. T., Lin, P. (2016) Gut microbial alterations associated with protection from autoimmune uveitis. *Invest. Ophthalmol. Vis. Sci.* **57**, 3747-3758.
- Otasevic, L., Zlatanovic, G., Stanojevic-Paovic, A., Miljkovic-Selimovic, B., Dinic, M., Djordjevic-Jocic, J., Stankovic, A. (2007) Helicobacter pylori: an underestimated factor in acute anterior uveitis and spondyloarthropathies? *Ophthalmologica* **221**, 6-13.
- Paques, M., Guyomard, J. L., Simonutti, M., Roux, M. J., Picaud, S., Legargasson, J. F., Sahel, J. A. (2007) Panretinal, high-resolution color photography of the mouse fundus. *Invest. Ophthalmol. Vis. Sci.* **48**, 2769-2774.
- Pawate, S., Sriram, S. (2010) The role of infections in the pathogenesis and course of multiple sclerosis. *Ann. Indian Acad. Neurol.* **13**, 80-86.
- Pélissier, M. A., Vasquez, N., Balamurugan, R., Pereira, E., Dossou-Yovo, F., Suau, A., Pochart, P., Magne, F. (2010) Metronidazole effects on microbiota and mucus layer thickness in the rat gut. *FEMS Microbiol. Ecol.* **73**, 601-610.
- Rizzo, A., Paolillo, R., Guida, L., Annunziata, M., Bevilacqua, N., Tufano, M. A. (2010) Effect of metronidazole and modulation of cytokine production on human periodontal ligament cells. *Int. Immunopharmacol.* **10**, 744-750.
- Rothova, A., Buitenhuis, H. J., Meenken, C., Brinkman, C. J. J., Linsen, A., Alberts, C., Luyendijk, L., Kijlstra, A. (1992) Uveitis and systemic disease. *Br. J. Ophthalmol.* **76**, 137-141.
- Sales-Campos, H., Soares, S. C., Oliveira, C. J. F. (2019) An introduction of the role of probiotics in human infections and autoimmune diseases. *Crit. Rev. Microbiol.* **45**, 413-432.
- Sarker, P., Mily, A., Al Mamun, A., Jalal, S., Bergman, P., Raqib, R., Gudmundsson, G., H., Agerberth, B. (2014) Ciprofloxacin affects host cells by suppressing expression of the endogenous antimicrobial peptides cathelicidins and beta-defensin-3 in colon epithelia. *Antibiotics* **3**, 353-374.
- Scher, J. U., Abramson, S. B. (2011) The microbiome and rheumatoid arthritis. *Nat. Rev. Rheumatol.* **7**, 569-578.
- Sellon, R. K., Tonkonogy, S., Schultz, M., Dieleman, L. A., Grenther, W., Balish, E., Rennick, D. M., Sartor, R. B. (1998) Resident enteric bacteria are necessary for development of spontaneous colitis and immune system activation in interleukin-10-deficient mice. *Infect. Immun.* **66**, 5224-5231.
- Smith, P. M., Howitt, M. R., Panikov, N., Michaud, M., Gallini, C. A., Bohlooly-Y, M., Glickman, J. N., Garrett, W. S. (2013) The microbial metabolites, short-chain fatty acids, regulate colonic Treg cell homeostasis. *Science* **341**, 569-573.
- Sorini, Ch., Cosorich, I., Lo Conte, M., De Giorgi, L., Facciotti, F., Luciano, R., Rocchi M., Ferrarese, R., Sanvito, F., Canducci, F., Falcone, M. (2019) Loss of gut barrier integrity triggers activation of islet-reactive T cells and autoimmune diabetes. *Proc. Natl. Acad. Sci. USA* **116**, 15140-15149.
- Stehlikova, Z., Kostovcikova, K., Kverka, M., Rossmann, P., Dvorak, J., Novosadova, I., Kostovcik, M., Coufal, S., Srutkova, D., Prochazkova, P., Hudkovic, T., Kozakova, H., Stepankova, R., Rob, F., Juzlova, K., Hercogova, J., Tlaskalova-Hogenova, H., Jiraskova, Zakostelska, Z. (2019) Crucial role of microbiota in experimental psoriasis revealed by a gnotobiotic mouse model. *Front. Microbiol.* **10**, 236.
- Suttorp-Schulten, M. S. A., Jager, M. J., Kijlstra, A. (1996) Recent developments in the treatment of posterior uveitis. *Ocul. Immunol. Inflamm.* **4**, 207-217.
- Thurau, S. R., Chan, C., Nussenblatt, R. B., Caspi, R. R. (1997) Oral tolerance in a murine model of relapsing experimental autoimmune uveoretinitis (EAU): induction of protective tolerance in primed animals. *Clin. Exp. Immunol.* **109**, 370-376.
- Tlaskalova-Hogenova, H., Stepankova, R., Hudkovic, T., Tuckova, L., Cukrowska, B., Lodinova-Zadnikova, R., Kozakova, H., Rossmann, P., Bartova, J., Sokol, D., Funda, D. P., Borovska, D., Rehakova, Z., Sinkora, J., Hofman, J., Drastich, P., Kokesova, A. (2004) Commensal bacteria

- (normal microflora), mucosal immunity and chronic inflammatory and autoimmune diseases. *Immunol. Lett.* **93**, 97-108.
- Townes, J. M. (2010) Reactive arthritis after enteric infections in the United States: the problem of definition. *Clin. Infect. Dis.* **50**, 247-254.
- Ungaro, R., Bernstein, C. N., Geary, R., Hviid, A., Kolho, K. L., Kronman, M. P., Shaw, S., Van Krujningen, H., Colombel, J. F., Atreja, A. (2014) Antibiotics associated with increased risk of new-onset Crohn's disease but not ulcerative colitis: a meta-analysis. *Am. J. Gastroenterol.* **109**, 1728-1738.
- Wang, S. L., Wang, Z. R., Yang, C. Q. (2012) Meta-analysis of broad-spectrum antibiotic therapy in patients with active inflammatory bowel disease. *Exp. Ther. Med.* **4**, 1051-1056.
- Wen, L., Ley, R. E., Volchkov, P. Y., Stranges, P. B., Avanesyan, L., Stonebraker, A. C., Hu, C., Wong, F. S., Szot, G. L., Bluestone, J. A., Gordon, J. I., Chervonsky, A. V. (2008) Innate immunity and intestinal microbiota in the development of type 1 diabetes. *Nature* **23**, 1109-1113.
- Xu, H., Koch, P., Chen, M., Lau, A., Reid, D.M., Forrester, J.V. (2008) A clinical grading system for retinal inflammation in the chronic model of experimental autoimmune uveoretinitis using digital fundus images. *Exp. Eye Res.* **87**, 319-326.
- Zakostelska, Z., Malkova, J., Klimesova, K., Rossmann, P., Hornova, M., Novosadova, I., Stehliková, Z., Kostovcik, M., Hudcovic, T., Stepankova, R., Juzlova, K., Hercogova, J., Tlaskalova-Hogenova, H., Kverka, M. (2016) Intestinal microbiota promotes psoriasis-like skin inflammation by enhancing Th17 response. *PLoS One* **11**, 7.