

Original Article

Effect of Graviola (*Annona Muricata* L.) and Ginger (*Zingiber Officinale* Roscoe) on Diabetes Mellitus Induced in Male Wistar Albino Rats

(diabetes mellitus / glucose transporters / insulin resistance / glycosylated haemoglobin / *Annona* / ginger)

K. M. AL SYAAD¹, F. G. ELSAID^{1,2}, M. E. ABDRABOH², A. A. AL-DOAISS^{1,3}

¹Biology Department, College of Science, King Khalid University, Abha, Saudi Arabia

²Zoology Department, Faculty of Science, Mansoura University, Mansoura, Egypt

³Anatomy and Histology Department, Faculty of Medicine, Sana'a University, Sana'a, Republic of Yemen

Abstract. *Annona* and ginger have prominent uses in traditional medicine; their therapeutic properties have not been sufficiently explored. The ameliorative effect of *Annona* or ginger extracts on hyperglycaemia associated with oxidative stress, inflammation, and apoptosis in experimentally induced diabetes was addressed. Type 1 diabetes in male rats was induced by a single injection of streptozotocin (STZ; 40 mg/kg, i.p.), then *Annona* (100 mg/kg) or ginger (200 mg/kg) extracts were orally administered daily for 30 days. The *Annona* and ginger extracts ameliorated hyperglycaemia, insulin level, glycosylated haemoglobin (HbA1c) and insulin resistance (HOMA-IR) levels in the diabetic rats. The treatments significantly ameliorated liver function enzymes and total proteins; this was confirmed by histopathological examination of liver sections. *Annona* and ginger extracts significantly reduced elevated malondialdehyde (MDA) and restored activity of antioxidant enzymes in the liver such as glutathione peroxidase (GPx),

glutathione reductase (GR), superoxide dismutase (SOD), and catalase (CAT) and the hepatic content of reduced glutathione (GSH). The oxidative stress-dependent inflammation was regulated by both *Annona* and ginger extracts, which was indicated by down-regulation of TNF- α , NF- κ B, pro-apoptotic proteins Bax, p53, and anti-apoptotic protein Bcl-2. Moreover, the expression of insulin receptor (*INSR*) and glucose transporter 2 (*GLUT2*) genes was markedly regulated by both these extracts. The results suggest that *Annona* and ginger extracts ameliorate the hepatic damage resulting from diabetes by advocating antioxidants and modulating apoptotic mediator proteins in the liver of diabetic rats. In conclusion, *Annona* and ginger extracts have a potential therapeutic effect in the treatment of diabetes and its complications.

Introduction

Diabetes mellitus (DM) is a metabolic disorder characterized by hyperglycaemia. Diabetes may be caused by destruction of pancreatic β -cells, or abnormalities resulting in resistance to insulin action. Diabetes is associated with several complications in different organs such as the retina, the liver, the kidney, and the nerves, which are all freely permeable to glucose (Ashcroft and Rorsman, 2012). A considerable amount of evidence has accumulated indicating that the liver damage caused by hyperglycaemia is related to generation of free radicals that stimulates cellular injury by increased oxidative stress, which in turn contributes to the complications associated with diabetes (Tiwari et al., 2013). Oxidative stress is the playmaker in complications caused by poor glycaemic control. Generation of reactive oxygen species (ROS) leads to the activation of the mitochondrial pathway, which is part of the apoptotic process (Circu and Aw, 2010). Several studies have documented an increase of apoptosis in the hepatic damage of diabetic patients and experimentally induced diabetic animals

Received March 25, 2019. Accepted June 6, 2019.

This work was supported by Deanship of Scientific Research, King Khalid University, KSA [General research project, Grant number: KKU-G.R.P.-246-39].

Corresponding author: Fahmy G. Elsaid, Biology Department, College of Science, King Khalid University, KSA; Zoology Department, Faculty of Science, Mansoura University, Mansoura, Egypt. E-mail: felsaid@kku.edu.sa

Abbreviations: ALT – alanine aminotransferase; ANOVA – analysis of variance; AST – aspartate aminotransaminase; CAT – catalase; CV – central vein; DM – diabetes mellitus; GLUT2 – glucose transporter 2; GPx – glutathione peroxidase; GR – glutathione reductase; GSH – reduced glutathione; H&E – haematoxylin and eosin; INS-R – insulin receptor; MDA – malondialdehyde; NF- κ B – nuclear factor κ B; ROS – reactive oxygen species; SOD – superoxide dismutase; STZ – streptozotocin; TNF- α – tumour necrosis factor α .

(Loria et al., 2013; Rashid et al., 2013). Shivananjappa (2012) reported that streptozotocin (STZ) produced oxidative stress and depletion of antioxidants in the liver tissues. Oxidative stress attacks the integrity of hepatocytes and releases the liver enzymes such as alanine aminotransferase (ALT) and aspartate aminotransaminase (AST). Also, ROS affects the metabolic function of the liver by increasing serum total bilirubin and decreasing total protein content (Mohamed et al., 2016).

The modern synthetic antidiabetic drugs used to control glycaemia have wide side effects, causing a shift in focus to alternative forms of therapy based on natural drugs extracted from plants without side effects (Zhao et al., 2018). Some medicinal plants have a considerable role in attenuating the risk of diabetes mellitus and its concomitant syndromes. Ginger (*Zingiber officinale*) is a commonly used food spice in many countries. Several studies have demonstrated that ginger has a hypoglycaemic effect, antioxidant properties and anti-inflammatory function. A previous study demonstrated that the treatment with ginger extract alleviates fasting blood glucose and serum lipids in diabetic rats (Shanmugam et al., 2011). Another study reports that ginger increases the uptake of glucose by skeletal muscle fibres in rats (Li et al., 2012). Graviola (*Annona muricata*), also known as soursop, is a member of the *Annonaceae* family. *Annona* is extensively used as a traditional medicine against an array of diseases. *Annona* extract is rich in flavonoids, isoquinoline alkaloids and annonaceous acetogenins (M Barbalho et al., 2012).

Several studies have shown that *Annona* extract has a chemotherapeutic effect against cancer (Paul et al., 2013; Gavamukulya et al., 2014; Pieme et al., 2014). Moreover, it was reported that *Annona* extract has anti-proliferative efficacy, neuroprotective properties, anti-cancer efficacy, anti-inflammatory, hypoglycaemic, hypotensive, and antispasmodic effects (Gajalakshmi et al., 2012). A recent *in vitro* study has shown that *A. muricata* leaf extract was able to induce apoptosis in the colon and lung cancer cells (Moghadamtousi et al., 2014). Adeyemi et al. (2009) reported that treatment of diabetic rats with *Annona* leaf methanolic extract for two weeks reduced the blood glucose concentration from 21.64 to 4.22 mmol/l. Therefore, the current study aimed to investigate the potential beneficial effect of *Annona* and ginger extracts on the biochemical, histological and molecular changes associated with diabetes in Wistar albino rats.

Material and Methods

Streptozotocin (STZ) and *Annona* liquid extract were purchased from Sigma Co. (St. Louis, MO) and Rainforest Pharmacy Co. (Miami, FL), respectively. Ginger ethanolic extract (ginger rhizomes) was obtained from the local aromatherapy provider. About 100 g fresh rhizomes were peeled in fine pieces of variable sizes and extracted with 2 litres of 70% ethanol in a bottle for 72 h. The extract solution was filtered and then ethanol was

evaporated at room temperature for 5 days to give a semi-solid extract (Nasri et al., 2013). All other chemicals and kits were of highest chemical grade and purchased from standard confirmed companies.

Induction of diabetes

Diabetes induction was carried out by STZ in rats according to El-Missiry et al. (2015) as follows: diabetes was induced by single intraperitoneal (i.p) injection of STZ (40 mg/kg b.wt.) dissolved in 0.1 M cold sodium citrate buffer, pH 4.5, and 48 h after STZ injection, the blood glucose level was assayed by Elegance CT-X10 (Convergent Technologies GmbH & Co. KG, Frankenberg, Germany) and the rats with the blood glucose range above 250 mg/dl were considered as diabetic rats and used for the experiment.

Experimental design

Thirty-six adult male Wistar albino rats weighing 150–170 g obtained from the animal house of the college of science were maintained under controlled humidity, temperature and photoperiod (12 h light/12 h dark). Rats were fed commercial rodent pellet diet and water *ad libitum*. Care and use of animals were conducted under the supervision of the animal ethics committee. After one week of acclimatization, rats were randomly divided into six groups, six animals in each group. The first group served as a control, the second group received a daily dose of *Annona* extract (100 mg/kg b. wt.) (Florence et al., 2014) by oral gavage for 30 days, the third group received a daily dose of ginger extract (200 mg/kg b. wt.) (Al-Sharafi and Al-Sharafi, 2014) by oral gavage for 30 days, the fourth group served as diabetic control, the fifth group of diabetic rats received a daily dose of *Annona* extract (100 mg/kg b. wt.) by oral gavage for 30 days and the sixth group of diabetic rats received a daily dose of ginger extract (200 mg/kg b. wt.) by oral gavage for 30 days. At the end of the experiment, rats were anaesthetized with i.p. injection of ketamine/xylazine 10 ml/kg b. wt. (Parasuraman et al., 2010), blood was collected by cardiac puncture into a non-heparinized tube and into an EDTA tube. Serum and liver were carefully separated, and each sample was placed in a clean cupped tube and labelled and kept at -20°C for the following investigations.

Biochemical investigations

The serum glucose and insulin levels and HbA1c blood levels were assayed by using kits purchased from Spinreact (Girona, Spain), RayBiotech (Peachtree Corners, GA) and BioSystems (Barcelona, Spain), respectively. Homeostasis model assessment-insulin resistance (HOMA-IR) was calculated using the following equation ($\text{HOMA-IR} = (\text{Fasting insulin} \times \text{Fasting glucose})/22.5$) (Salgado et al., 2010). The serum liver function including alanine aminotransferase (ALT), aspartate aminotransaminase (AST), albumin, total bilirubin, and total protein was determined according to the manufacturer's instructions of Spinreact kit (Girona). Malon-

dialdehyde (MDA) concentration as lipid peroxidation products in the liver tissue was estimated using Bio-Diagnostic Kit (Dokki, Giza, Egypt). The enzymatic antioxidant activities such as superoxide dismutase (SOD), catalase (CAT), glutathione peroxidase (GPx), and glutathione reductase (GR) and the concentration of reduced glutathione in the liver tissue was determined according to the manufacturer's instructions of Bio-Diagnostic Kit. Quantitative determination of serum tumour necrosis factor α (TNF- α) and nuclear factor κ B (NF- κ B) were performed by using the sandwich enzyme immunoassay technique according to the instructions of the kit purchased from R&D Systems (Minneapolis, MN) and Cloud-Clone Crop (Houston, TX), respectively. Apoptosis was examined in the liver tissue by determining levels of Bax, Bcl-2 and p53 using the sandwich enzyme immunoassay technique applied according to the instructions of the kit purchased from Cloud-Clone Crop and RayBiotech, respectively.

Molecular investigations

Extraction of total RNA from the liver tissue was performed by using the Qiagen RNeasy kit (Manchester, UK) according to the manufacturer's protocol. The quantity and quality of RNA were analysed using a NanoDrop spectrophotometer. cDNA was synthesized from total RNA using Moloney murine leukaemia virus reverse transcriptase (Fermentas, Waltham, MA), following the instructions of the supplier. The mRNA expression of glucose transporter 2 (*GLUT2*) and insulin receptor (*INSR*) genes was measured using the PCR technique with sequences of specific primers shown in Table 1 at PCR conditions: initial denaturation at 95 °C for 5 min, followed by 35 cycles at 52 °C for 1 min, 55 °C for 1 min, and 72 °C for 1 min and 58 °C for glyceraldehyde-3-phosphate dehydrogenase for 30 s each, and 72 °C for 1 min. Final extension at 72 °C was done for 10 min. Amplified PCR products were electrophoresed in 1 % agarose gel. The gel was run for 60 min and then visualized and photographed using an ultraviolet transilluminator gel documentation system.

Histopathological investigations

A fresh sample of the liver from each rat was fixed in neutral buffered formalin (10%) for 24 h for histopathological examination, then dehydrated through ascending concentrations of ethanol, cleared in xylene, embedded in paraffin, and sectioned at 5 μ m. The sections were then routinely stained with haematoxylin and eosin (H&E). The sections were examined by light microsc-

py for histopathological changes, and images were captured using a bright field Olympus (Tokyo, Japan) light microscope with an Amscope MU1000 camera.

Statistical analysis

All grouped data were statistically performed with the Prism (GraphPad Prism, 6.01) software. Differences among groups were evaluated by one-way analysis of variance (ANOVA) followed by Duncan's multiple range tests. All values were expressed as the mean \pm SE of six animals per group. The percentage of changes in the treated groups was calculated.

Results

Serum glucose, insulin, HbA-1c, and HOMA-IR levels

The effect of *Annona* and ginger extract on blood glucose in the different animal groups was studied during the experimental period. The diabetic rats showed a significant ($P < 0.01$) increase in the blood glucose during the experimental period compared to the control group. Oral administration of *Annona* and ginger extracts to the diabetic rats showed a marked amelioration during the experimental period (Fig. 1) and at the end of the experimental period (Table 2) compared with the diabetic group, but the glucose level was still higher than in the control group. The serum glucose and HbA-1c levels

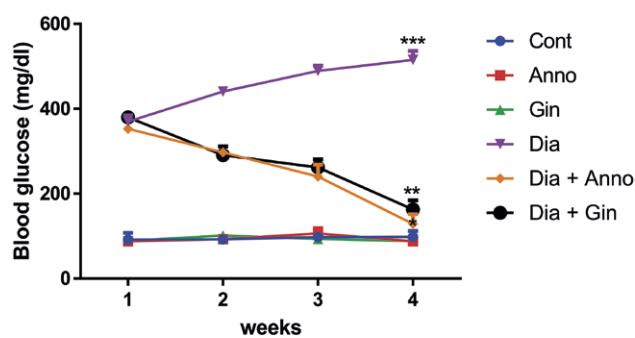


Fig. 1. Effects of *Annona* and ginger extracts on blood glucose in rats in different groups during the experimental period. The values are expressed as the means \pm SEM (N = 6). *Significant at $P < 0.05$, **significant at $P < 0.01$, and ***significant at $P < 0.001$. *, **, *** indicate comparisons with respect to the control group.

Table 1. Oligonucleotides used in the study

| Primer | Forward | Reverse |
|---------------|-----------------------|------------------------|
| <i>GLUT 2</i> | GTCCAGAAAGCCCCAGATACC | GTCACATCCTCAGTTCTCTTAG |
| <i>INS-R</i> | GCCTCTACAACCTGATGAAC | ACAGATGTCTCCACACTCC |
| <i>GAPDH</i> | ACCACAGTCCATGCCATCAC | TCCACCACCCTGTTGCTGTA |

Table 2. Effects of *Annona* or ginger extract on the serum glucose (mg/dl) and insulin (pg/ml) levels and the percentages of HbA1c and HOMA-IR in rats in different groups at the end of the experimental period

| | Cont | Anno | Gin | Dia | Dia + Anno | Dia + Gin |
|---------|--------------|--------------|--------------|-----------------|---------------|----------------|
| Glucose | 96.20 ± 3.09 | 97.20 ± 2.65 | 99.20 ± 5.12 | 501.4 ± 7.47*** | 148.2 ± 9.40* | 164.6 ± 8.71** |
| Insulin | 20.07 ± 0.88 | 19.90 ± 0.66 | 19.61 ± 0.85 | 6.34 ± 0.31*** | 16.80 ± 0.33* | 16.30 ± 0.48** |
| HbA1c | 3.82 ± 0.22 | 3.89 ± 0.22 | 4.11 ± 0.14 | 9.02 ± 0.13*** | 4.74 ± 0.35* | 4.99 ± 0.10** |
| HOMA-IR | 4.76 ± 0.25 | 4.88 ± 0.32 | 4.80 ± 0.31 | 7.78 ± 0.31*** | 6.14 ± 0.35* | 6.42 ± 0.27** |

The values are expressed as the means ± SEM (N = 6). *Significant at P < 0.05, **significant at P < 0.01, and ***significant at P < 0.001. *, **, *** indicate comparisons with respect to the control group.

were significantly (P < 0.001) increased after diabetic induction associated with a significant decrease in serum insulin levels and higher HOMA-IR compared to the control rats (Table 2). Treatment of diabetic rats with *Annona* and ginger extracts for 30 days showed significantly (P < 0.05, P < 0.01) ameliorated serum glucose and HbA-1c levels, with a significant increase in insulin levels and lower HOMA-IR compared to the diabetic rats, but still higher than the control levels (Table 2).

GLUT2 and INSR gene expression

PCR analysis showed that the *INSR* gene expression in the liver tissue was decreased in diabetic rats and it was markedly up-regulated in the *Annona* extract-treated diabetic rats (Fig. 2). Also, the *GLUT2* gene expression in the liver was increased markedly in the diabetic condition and it reversed to near the control value in *Annona* or ginger extract-treated diabetic rats (Fig. 2).

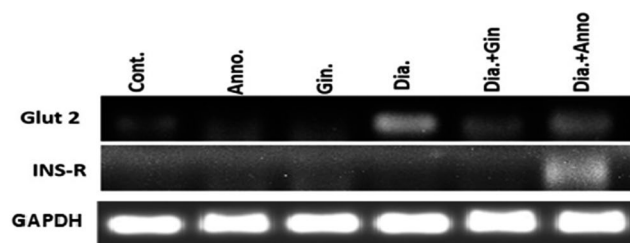


Fig. 2. Effects of *Annona* and ginger extracts on *GLUT2* and *INSR* gene expression in rats in different groups during the experimental period

Serum markers of liver function

Compared to control rats, the liver function in the serum, including enzymatic activities of AST and ALT, and total bilirubin levels were significantly higher, whereas the level of total protein and albumin was significantly lower in the diabetic rats (Table 3). The treatment of diabetic rats with *Annona* extract or ginger extract caused marked amelioration in the liver function enzymes and proteins towards control compared to the diabetic group (Table 3).

Oxidative stress and antioxidants

A significant increase in MDA concentration represented by lipid peroxidation products in the liver of diabetic rats was used as indication for oxidative stress (Fig. 3). In addition, a significant decrease (P < 0.001) was shown in the activities of enzymatic antioxidants such as SOD, CAT, GPx, GR, and GSH concentration in the liver of diabetic rats. Oral administration of *Annona* or ginger extracts prevented elevation of the MDA concentration and the decrease in the activities of enzymatic antioxidants such as SOD, CAT, GPx, GR, and GSH concentration in the liver of diabetic rats (Fig. 3).

Serum inflammation markers

Diabetic rats have significantly higher concentrations of TNF- α and NF- κ B compared with the control levels. Oral administration of *Annona* or ginger extract ameliorated the elevation of TNF- α and NF- κ B concentrations in the serum and showed a significant change compared

Table 3. Effects of *Annona* and ginger extracts on the serum liver function enzymes and protein levels in rats in different groups at the end of the experimental period

| | Cont | Anno | Gin | Dia | Dia + Anno | Dia + Gin |
|-------------|--------------|--------------|--------------|-----------------|---------------|----------------|
| ALT (U/l) | 21.54 ± 2.27 | 21.68 ± 2.43 | 22.16 ± 1.40 | 67.06 ± 2.05*** | 31.54 ± 2.23* | 32.64 ± 2.25* |
| AST (U/l) | 74.24 ± 3.96 | 73.77 ± 3.80 | 73.61 ± 5.14 | 170.9 ± 3.97*** | 97.18 ± 5.99* | 100.1 ± 4.03** |
| T.B (mg/dl) | 0.13 ± 0.01 | 0.13 ± 0.01 | 0.13 ± 0.01 | 0.68 ± 0.01*** | 0.18 ± 0.01* | 0.19 ± 0.01** |
| Alb (mg/dl) | 4.94 ± 0.30 | 5.00 ± 0.20 | 4.99 ± 0.10 | 1.02 ± 0.17*** | 3.78 ± 0.21* | 3.70 ± 0.33* |
| T.P (mg/dl) | 6.66 ± 0.37 | 6.60 ± 0.20 | 6.51 ± 0.40 | 2.48 ± 0.48*** | 4.76 ± 0.27** | 4.58 ± 0.21** |

The values are expressed as the means ± SEM (N = 6). *Significant at P < 0.05, **significant at P < 0.01, and ***significant at P < 0.001. *, **, *** indicate comparisons with respect to the control group.

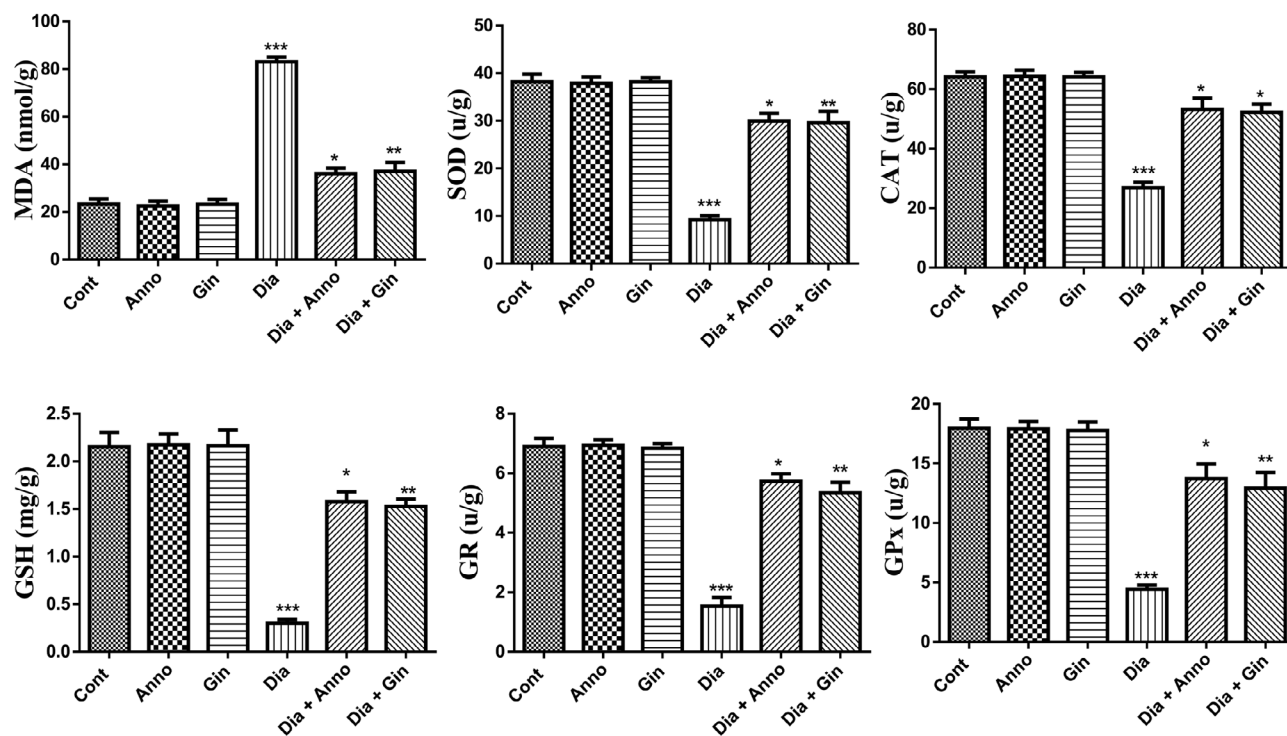


Fig. 3. Effects of *Annona* and ginger extracts on MDA, SOD, CAT, GPx, GR, and GSH in rats in different groups during the experimental period. The values are expressed as the means \pm SEM (N = 6). *Significant at $P < 0.05$, **significant at $P < 0.01$, and ***significant at $P < 0.001$. *, **, *** indicate comparisons with respect to the control group.

with the diabetic rats, while insignificant changes were observed compared with the control (Fig. 4).

Apoptosis

The mechanism of apoptosis in the liver of diabetic rats was assessed through the regulatory proteins of the mitochondrial pathway such as p53, Bax and Bcl-2. A significant increase ($P < 0.001$) in the p53 and Bax levels and a significant decrease ($P < 0.001$) in Bcl-2 were shown in diabetic rats compared with the healthy control animals. These changes were significantly ameliorated when the diabetic rats were orally treated with the *Annona* or ginger extract (Fig. 5).

Histopathological examination

Microphotographs of the liver showed that the liver architecture of all control animals was well preserved and kept intact normal histological components of the hepatic lobules and portal areas (Fig. 6). The liver sections of the diabetic group exhibited necrosis, blood sinusoids congestion, hydropic degeneration, and infiltrated neutrophils. In addition, pyknosis was observed in the hepatocytes (Fig. 6D). Also, vacuolated swelling of the hepatocyte cytoplasm was noticed in the diabetic rats. The liver sections of the animals treated with ginger (Fig. 6C) and diabetic rats + ginger (Fig. 3F) showed

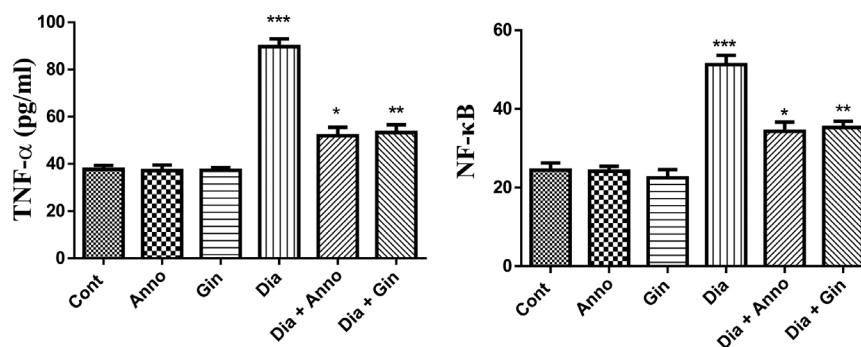


Fig. 4. Effects of *Annona* and ginger extracts on TNF- α and NF- κ B in rats in different groups during the experimental period. The values are expressed as the means \pm SEM (N = 6). *Significant at $P < 0.05$, **significant at $P < 0.01$, and ***significant at $P < 0.001$. *, **, *** indicate comparisons with respect to the control group.

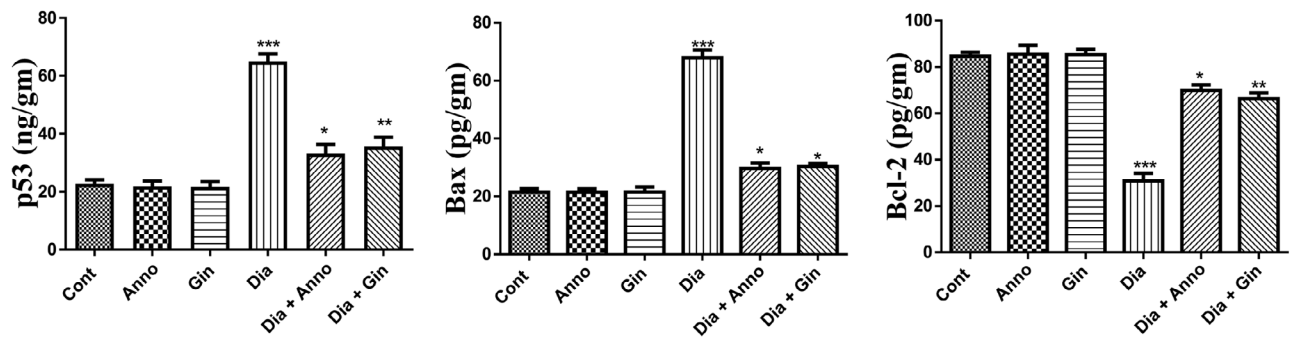


Fig. 5. Effects of *Annona* and ginger extracts on Bcl-2, Bax and p53 in rats in different groups during the experimental period. The values are expressed as the means \pm SEM (N = 6). *Significant at $P < 0.05$, **significant at $P < 0.01$, and ***significant at $P < 0.001$. *, **, *** indicate comparisons with respect to the control group.

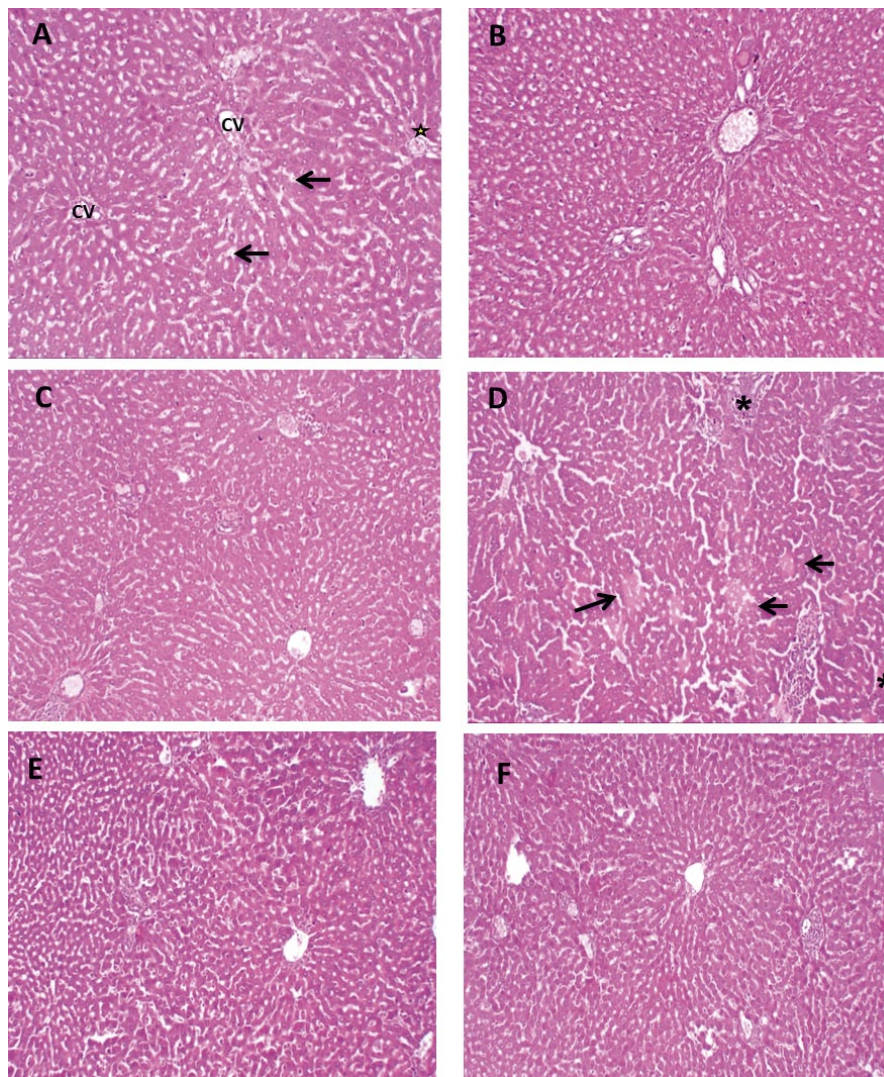


Fig. 6. (A): Microphotograph of a section of control liver showing normal morphology and absence of lesion area, with normally appearing central vein (CV); parallel cords of hepatocytes radiate from the central vein towards the periphery of the hepatic lobule and are separated by sinusoidal spaces (arrows) and normal portal area (*). H&E; 100 \times . (B): Microphotograph of a section of liver from a rat treated with *Annona* showing normal hepatic lobule architecture. H&E; 100 \times . (C) Microphotographs of a section of liver from a rat treated with ginger showing normal hepatic lobule architecture. H&E; 100 \times . (D): Microphotograph of a section of liver from a diabetic rat stained with H&E showing focal congestive necrosis (arrows) and infiltrating neutrophils (*) with hydropic degeneration (small arrows) at magnification 100 \times . (E): Microphotograph of a section of liver from a diabetic rat + *Annona* showing normal hepatic lobule architecture. H&E; 100 \times . (F): Microphotograph of a section of liver from a diabetic rat + ginger showing normal hepatic lobule architecture. H&E; 100 \times .

normal hepatic lobules. The liver sections of the animals treated with *Annona* (Fig. 6B) and diabetic rats + *Annona* (Fig. 6E) showed normal hepatic lobules and absence of marked histological alterations.

Discussion

Diabetes mellitus is a chronic metabolic disorder characterized by hyperglycaemia, increased water intake and polyuria accompanied by many complications such as liver dysfunction, cardiomyopathy, nephropathy, and neuropathy (Ghosh et al., 2015). Furthermore, there is widespread acceptance of a possible role for ROS, generated as a result of hyperglycaemia, in induction of many secondary complications of diabetes (Bhandari and Pillai, 2005). The modern synthetic anti-diabetic drugs used to control glycaemia have wide side effects, resulting in a shift in focus to alternative forms of therapy based on natural drugs extracted from plants without side effects (Zhao et al., 2018). Therefore, we have investigated the effect of *Annona* and ginger extracts on the liver damage induced by streptozotocin in rats. Our study showed a significant increase in the blood glucose levels in diabetic rats with a decrease in insulin levels (Table 2), which may be due to the destructive effect of STZ on β -cells with a subsequent decrease in insulin biosynthesis and secretion, and impaired glucose (Rorsman and Ashcroft, 2017). This finding was supported by Fu et al. (2010), who reported that STZ displayed cytotoxicity on pancreatic islet β -cells. Furthermore, intracellular metabolism of STZ produces free radicals that initiate alkylation of β -cell DNA strands and its breaks (Bolzán and Bianchi, 2002). Also, reduction of the insulin level causes gluconeogenesis and glycogenolysis that increase the blood glucose level, with a gross loss of the liver and muscle glycogen content and fats due to the increased protein catabolism and lipolysis (Qaid and Abdelrahman, 2016).

Our study showed that administration of *Annona* and ginger extracts ameliorated the elevation of serum glucose, HbA1c and HOMA-IR levels and the decrease of the insulin level in STZ-treated rats at the end of the experimental period. The mechanism underlying the hypoglycaemic effect of *Annona* and ginger extracts may be due to the restored insulin sensitivity and increased insulin secretion from the protected or regenerated β -cells (Shanmugam et al., 2011; Florence et al., 2014). The present results are consistent with the findings from a previous study reporting that the *Annona* extract exhibited an anti-diabetic effect and improved insulin sensitivity (Ahalya et al., 2014). In the current study, the liver *GLUT2* gene expression down-regulation and *INSR* gene expression up-regulation after diabetic rats were treated with *Annona* and ginger extracts may be due to the antioxidant property of these extracts. *GLUT2* enhances glucose transport through the hepatocyte membranes in response to the insulin hormone (Leturque et al., 2009). $\text{TNF-}\alpha$, one of the major proinflammatory cytokines, plays a role in wound healing, haematopoie-

sis and many other biological events. The present study showed that the increase in the serum $\text{TNF-}\alpha$ and $\text{NF-}\kappa\text{B}$ in diabetic rats may be due to hyperglycaemia, insulin resistance and damage in β -cells resulting from the generation of free radicals (Dokumacioglu et al., 2018); this elevation of $\text{TNF-}\alpha$ activates $\text{NF-}\kappa\text{B}$, which increases its level in the serum of diabetic animals. This finding is supported by the present results showing that *Annona* and ginger extracts ameliorate the elevation of the serum levels of $\text{TNF-}\alpha$ and $\text{NF-}\kappa\text{B}$ in diabetic rats. Ko and Leung (2010) have reported that ginger extract reduces the serum levels of $\text{TNF-}\alpha$. Improving insulin signal transduction in adipose tissues and muscles may be the reason for the reduction of $\text{TNF-}\alpha$ (Perez-Matute et al., 2009).

Our study demonstrated that the serum total protein and albumin levels were significantly decreased, while the serum total bilirubin and activities of AST and ALT were significantly increased in the diabetic rats. These results are comparable with other studies explaining that the marked changes in total protein levels reflect disorders in the synthesis and metabolism of proteins (Aggarwal and Gupta, 2012; Sharma et al., 2014). Our results are also in accordance with Arya et al., (2012), who reported that there was a significant decrease in plasma protein and albumin levels in STZ-induced diabetic rats due to the liver damage. Diabetic induction by STZ causes outflow AST and ALT from the liver cytosol into the bloodstream, leading to hepatic damage (Harris, 2005; Erejuwa et al., 2012). Xie et al. (2014) and You et al. (2015) found that the damage in hepatocytes may be due to the increase of oxidative stress and disturbance of enzyme biosynthesis. Also, the elevation of total bilirubin due to the decrease of liver uptake, conjugation, or increased total bilirubin production due to the accelerated RBC haemolysis indicated the presence of both haematological and liver problems (Vitek, 2012). The results of the present study revealed that *Annona* and ginger extracts ameliorate the decrease of serum total proteins and albumin. These results are compatible with the findings obtained by Atta et al. (2010), who reported effects of ginger extracts on the liver damage. Also in this line, Arthur et al. (2012) documented the hepatoprotective activity of the *Annona* extract against tetrachloride and acetaminophen-induced liver damage.

Oxidative stress is widely accepted as a fundamental factor in the development of diabetes and complications (Folli et al., 2011). Many publications have reported the role of oxidative stress in diabetic condition due to the increased generation of ROS and deficient antioxidant defence (Asmat et al., 2016; Lawson et al., 2017). The increased levels of MDA with decreased levels of total GSH and activities of SOD, CAT, GPx, and GR are the main reason for the excessive oxidative stress in the liver of diabetic rats. Treatment of diabetic rats with *Annona* and ginger extracts decreased the MDA levels accompanied with increased GSH content in the liver and activity of hepatic enzymatic antioxidants such as SOD, CAT, GPx, and GR. Flavonoids and other active

components of the *Annona* (Florence et al., 2014) and ginger (Flores-Sanchez and Gang, 2013) extracts have the ability to scavenge the free radicals produced throughout the progression of diabetes mellitus by their active ingredients. Treatment of diabetic rats with *Annona* or ginger extract ameliorated the STZ-induced programmed cell death in hepatic tissues by regulating pro-apoptotic proteins such as Bax and P53, and anti-apoptotic proteins such as Bcl-2. These results indicate marked modulation of both mitochondrial and death receptor apoptotic pathways in the liver of *Annona* or ginger extract-treated diabetic rats.

Histological analysis revealed that neutrophil infiltrate-accompanied necrosis was observed in the livers of the diabetic rats (Asante et al., 2016). Neutrophil-induced damage is probably secondary to necrosis development. The hepatic lobules of diabetic rats demonstrated haemorrhages, dilatation and congestion of blood sinusoids in comparison with the control group (Fig. 6) (Abed et al., 2015). This alteration could have resulted from the vasodilator effect of the treatment and might indicate an impact on the cell membrane permeability of endothelial blood vessels. Sinusoidal dilatation and congestion can also occur in the setting of systemic inflammatory, granulomatous disorders. Vacuolated swelling of the hepatocyte cytoplasm was noticed in the diabetic rats (Badawy et al., 2017). This might have resulted from the ion and fluid homeostasis imbalance that led to an increase of intracellular water content together with massive influx of water and Na⁺ due to the acute liver injury, leading to lysosomal hydrolytic enzyme leakages and cellular degeneration (Golod, 2018). On the other hand, the liver sections of *Annona* and ginger-treated rats showed a normal hepatic lobular architecture with no signs of cell toxicity

Conclusion

The potential roles of *Annona* and ginger extracts in eradicating the liver damage induced by STZ are pleiotropic and include anti-hyperglycaemic, anti-apoptotic, antioxidant, and anti-inflammatory activities. They may play an important role in the modulation of inflammation and apoptotic cell signalling in the liver of diabetic rats.

Conflict of interest

The authors declare that there is no conflict of interest.

References

- Abed, S. A., El-Shazely, M., Ahmed K. A., Abdel-mawla, E. M., Ibrahim, A. K. (2015) Therapeutic effects of *Spirulina platensis* on streptozotocin-induced diabetic rats. *Egypt. J. Comp. Path & Clinic Path.* **28**, 18-31.
- Adeyemi, D. O., Komolafe, O. A., Adewole, O. S., Obuotor, E. M., Adenowo, T. K. (2009) Anti hyperglycemic activities of *Annona muricata* (Linn). *Afr. J. Tradit. Complement Altern. Med.* **6**, 62-69.
- Aggarwal, N. Gupta, P. (2012) Effect of petroleum ether extract of *Sesbania sesban* (Merr.) roots in streptozotocin (STZ) induced diabetes in mice. *Asian Pacific J. Tropical Biomed.* **2**(Suppl), S1254-S1260.
- Ahalya, B. Shankar, K. R., Kiranmayi G. (2014) Exploration of anti-hyperglycemic and hypolipidemic activities of ethanolic extract of *Annona muricata* bark in alloxan induced diabetic rats. *Int. J. Pharm. Sci. Rev. Res.* **25**, 21-27.
- Al-Sharafi, N. M., Al-Sharafi, M. R. (2014) Study the effects of ginger (*Zingiber officinale*) extract on serum lipid in hypothyroidism male rats induce by propylthiouracil. *Kufa J. Vet. Med. Sci.* **5**, 2, 258-266.
- Arthur, F. K., Larbie, C., Woode E., Terlabi E. O. (2012) Evaluation of hepatoprotective effect of aqueous extract of *Annona muricata* (Linn.) leaf against carbon tetrachloride and acetaminophen-induced liver damage. *J. Nat. Pharm.* **3**, 25-30.
- Arya, A., Cheah, S. C., Looi, C. Y., Taha, H., Mustafa, M. R., Mohd M. A. (2012) The methanolic fraction of *Centrathrum anthelminticum* seed downregulates pro-inflammatory cytokines, oxidative stress, and hyperglycemia in STZ-nicotinamide-induced type 2 diabetic rats. *Food Chem. Toxicol.* **50**, 4209-4220.
- Asante, D.-B., Effah-Yeboah E., Barnes, P., Abban, H. A., Ameyaw, E. O., Boampong, J. N., Ofori, E. G., Dadzie, J. B. (2016) Antidiabetic effect of young and old ethanolic leaf extracts of *Vernonia amygdalina*: a comparative study. *J. Diabetes Res.* **2016**, 1-13.
- Ashcroft, F. M., Rorsman, P. (2012) Diabetes mellitus and the β cell: the last ten years. *Cell* **148**, 1160-1171.
- Asmat, U., Abad, K., Ismail, K. (2016) Diabetes mellitus and oxidative stress – a concise review. *Saudi Pharm. J.* **24**, 547-553.
- Atta, A., Elkoly, T., Mouneir, S., Kamel, G., Alwabel, N., Zaher, S. (2010) Hepatoprotective effect of methanol extracts of *Zingiber officinale* and *Cichorium intybus*. *Indian J. Pharm. Sci.* **72**, 564-274.
- Badawy, G., Sakr, S. A., El-Borm, H. T. (2017) The ameliorative role of curcumin administration against betamethasone-induced maternal and fetal hepatotoxicity in rats. *J. Biosci. App. Res.* **3**, 118-130.
- Barbalho, S. M., Alvares Goulart, R. D., Maria Vasques Fari-nazzi-Machado, F., da Silva Soares de Souza M., Cincotto dos Santos Bueno, P., Landgraf Guiguer, E., Cressoni Araujo, A. Groppo, M. (2012) *Annona* sp: plants with multiple applications as alternative medicine. *Curr. Bioact. Compd.* **8**, 277-286.
- Bhandari, U., Pillai, K. (2005) Effect of ethanolic extract of *Zingiber officinale* on dyslipidaemia in diabetic rats. *J. Ethnopharmacol.* **97**, 227-230.
- Bolzán, A. D., Bianchi, M. S. (2002) Genotoxicity of streptozotocin. *Mutat Res.* **512**, 121-134.
- Circu M. L., T. Y. Aw (2010) Reactive oxygen species, cellular redox systems, and apoptosis. *Free Radic. Biol. Med.* **48**, 749-762.
- Dokumacioglu, E., Iskender, H., Sen, T. M., Ince I., Dokumacioglu, A., Kanbay, Y., Erbas, E., Saral, S. (2018) The effects of hesperidin and quercetin on serum tumor necrosis factor- α and interleukin-6 levels in streptozotocin-induced diabetes model. *Pharmacogn. Mag.* **14**, 167-173.

- El-Missiry, M. A., Amer, M. A., Hemieda, F. A., Othman, A. I., Sakr, D. A., Abdulhadi, H. L. (2015) Cardioameliorative effect of punicalagin against streptozotocin-induced apoptosis, redox imbalance, metabolic changes and inflammation. *Egypt. J. Zool.* **65**, 247-260.
- Erejuwa, O., Sulaiman, S., Wahab, M., Sirajudeen, K., Salleh, M., Gurtu, S. (2012) Hepatoprotective effect of tualang honey supplementation in streptozotocin-induced diabetic rats. *Int. J. App. Res. Nat. Prod.* **4**, 37-41.
- Florence, N. T., Benoit, M. Z., Jonas, K., Alexandra, T., Désiré, D. D., Pierre, K., Théophile, D. (2014) Antidiabetic and antioxidant effects of *Annona muricata* (Annonaceae), aqueous extract on streptozotocin-induced diabetic rats. *Int. J. App. Res. Nat. Prod.* **4**, 784-790.
- Flores-Sanchez, I. J., Gang, D. R. (2013) Inhibition of hydroxycinnamoyl-CoA thioesterases in ginger (*Zingiber officinale Roscoe*) and turmeric (*Curcuma longa L.*) by lipase inhibitors. *Plant Physiol. Biochem.* **72**, 46-53.
- Folli, F., Corradi, D., Fanti, P., Davalli, A., Paez, A., Giaccari, A., Perego, C., Muscogiuri, G. (2011) The role of oxidative stress in the pathogenesis of type 2 diabetes mellitus micro- and macrovascular complications: avenues for a mechanistic-based therapeutic approach. *Curr. Diabetes Rev.* **7**, 313-324.
- Fu, Y.Y., Kang, K. J., Ahn, J. M., Kim, H. R., Na, K. Y., Chae, D. W., Kim, S., Chin, H. J. (2010) Hyperbilirubinemia reduces the streptozotocin-induced pancreatic damage through attenuating the oxidative stress in the Gunn rat. *Tohoku J. Exp. Med.* **222**, 265-273.
- Gajalakshmi, S., Vijayalakshmi, S., Devi Rajeswari, V. (2012) Phytochemical and pharmacological properties of *Annona muricata*: a review. *Int. J. Pharm. Pharm. Sci.* **4**, 3-6.
- Gavamukulya, Y., Abou-Elella, F., Wamunyokoli, F., AEl-Shemy, H. (2014) Phytochemical screening, anti-oxidant activity and in vitro anticancer potential of ethanolic and water leaves extracts of *Annona muricata* (Graviola). *Asian Pac. J. Trop. Med.* **7**, S355-S363.
- Ghosh, S., Bhattacharyya, S., Rashid, K., Sil, P. C. (2015) Curcumin protects rat liver from streptozotocin-induced diabetic pathophysiology by counteracting reactive oxygen species and inhibiting the activation of p53 and MAPKs mediated stress response pathways. *Toxicol. Rep.* **2**, 365-376.
- Golod, M. (2018) *Regional Differences in Na⁺/K⁺-ATPase Expression in the Mouse and Rat Brain*. Queen's University Kingston, Ontario, Canada. 1-109.
- Harris, E. H. (2005) Elevated liver function tests in type 2 diabetes. *Clin. Diabetes* **23**, 115-119.
- Ko, J. K., Leung, C. C. (2010) Ginger extract and polaprezinc exert gastroprotective actions by anti-oxidant and growth factor modulating effects in rats. *J. Gastroenterol. Hepatol.* **25**, 1861-1869.
- Lawson, M., Jomova, K., Poprac, P., Kuča, K., Musilek, K., Valko, M. (2017) Free radicals and antioxidants in human disease. In: *Nutritional Antioxidant Therapies: Treatments and Perspective*, pp. 283-305, Springer, Cham.
- Leturque, A., Brot-Laroche, E., Le Gall, M. (2009) GLUT2 mutations, translocation, and receptor function in diet sugar managing. *Am. J. Physiol. Endocrinol. Metab.* **296**, E985-E992.
- Li, Y., Tran, V. H., Duke, C. C., Roufogalis, B. D. (2012) Preventive and protective properties of *Zingiber officinale* (ginger) in diabetes mellitus, diabetic complications, and associated lipid and other metabolic disorders: a brief review. *Evid. Based Complement. Alternat. Med.* **2012**, 516870.
- Loria, P., Lonardo, A., Anania, F. (2013) Liver and diabetes. A vicious circle. *Hepatol. Res.* **43**, 51-64.
- Moghadamtousi, S. Z., Karimian, H., Rouhollahi, E., Paydar, M., Fadaeinasab, M., Kadir H. A. (2014) *Annona muricata* leaves induce G1 cell cycle arrest and apoptosis through mitochondria-mediated pathway in human HCT-116 and HT-29 colon cancer cells. *J. Ethnopharmacol.* **156**, 277-289.
- Mohamed, J., Nafizah, A. N., Zariyantey, A. Budin, S. B. (2016) Mechanisms of diabetes-induced liver damage: the role of oxidative stress and inflammation. *Sultan Qaboos Univ. Med. J.* **16**, e132-e142.
- Nasri, H., Nematbakhsh, M., Ghobadi, S., Ansari, R., Shahinfard, N., Rafieian-Kopaei, M. (2013) Preventive and curative effects of ginger extract against histopathologic changes of gentamicin-induced tubular toxicity in rats. *Int. J. Prev. Med.* **4**, 316-321.
- Parasuraman, S., Raveendran, R., Kesavan, R. (2010) Blood sample collection in small laboratory animals. *J. Pharmacol. Pharmacother.* **1**, 87-93.
- Paul, J., Gnanam, R., Jayadeepa, R. M., Arul, L. (2013) Anti cancer activity on Graviola, an exciting medicinal plant extract vs various cancer cell lines and a detailed computational study on its potent anti-cancerous leads. *Curr. Top Med. Chem.* **13**, 1666-1673.
- Perez-Matute, P., Zulet M. A., Martínez, J. A. (2009) Reactive species and diabetes: counteracting oxidative stress to improve health. *Curr. Opin. Pharmacol.* **9**, 771-779.
- Pieme, C. A., Kumar, S. G., Dongmo, M. S., Moukette, B. M., Boyoum, F. F., Ngogang, J. Y., Saxena, A. K. (2014) Antiproliferative activity and induction of apoptosis by *Annona muricata* (Annonaceae) extract on human cancer cells. *BMC Complement. Altern. Med.* **14**, 516.
- Qaid, M. M., Abdelrahman M. M. (2016) Role of insulin and other related hormones in energy metabolism. A review. *Cogent Food Agric.* **2**, 1267691.
- Rashid, K., Das, J., Sil, P. C. (2013) Taurine ameliorate alloxan induced oxidative stress and intrinsic apoptotic pathway in the hepatic tissue of diabetic rats. *Food Chem. Toxicol.* **51**, 317-329.
- Rorsman, P., Ashcroft, F. M. (2017) Pancreatic β -cell electrical activity and insulin secretion: of mice and men. *Physiol. Rev.* **98**, 117-214.
- Salgado, A. L., Carvalho, L. D., Oliveira, A. C., Santos, V. N., Vieira, J. G., Parise, E. R. (2010) Insulin resistance index (HOMA-IR) in the differentiation of patients with non-alcoholic fatty liver disease and healthy individuals. *Arq. Gastroenterol.* **47**, 165-169.
- Shanmugam, K. R., Mallikarjuna, K., Nishanth, K., Kuo, C. H., Reddy, K. S. (2011) Protective effect of dietary ginger on antioxidant enzymes and oxidative damage in experimental diabetic rat tissues. *Food Chem.* **124**, 1436-1442.
- Sharma, S., Choudhary, M., Bhardwaj, S., Choudhary, N., Rana, A. C. (2014) Hypoglycemic potential of alcoholic

- root extract of *Cassia occidentalis* Linn. in streptozotocin induced diabetes in albino mice. *Bull. Fac. Pharm. Cairo Univ.* **2014**, 211-217.
- Shivananjappa, M. M. (2012) Taurine attenuates maternal and embryonic oxidative stress in a streptozotocin-diabetic rat model. *Reprod. Biomed. Online* **24**, 558-566.
- Tiwari, B. K., Pandey, K. B., Abidi, A., Rizvi, S. Y. (2013) Markers of oxidative stress during diabetes mellitus. *J. Biomark.* **2013**, 1-9.
- Vitek, L. (2012) The role of bilirubin in diabetes, metabolic syndrome, and cardiovascular diseases. *Front. Pharmacol.* **3**, 1-7.
- Xie, M., Chen, D., Zhang, F., Willsky, G. R., Crans, D. C., Ding, W. (2014) Effects of vanadium (III, IV, V)-chlorodipicolinate on glycolysis and antioxidant status in the liver of STZ-induced diabetic rats. *J. Inorg. Biochem.* **136**, 47-56.
- You, Y., Ren, T., Zhang, S., Shirima, G. G., Cheng, Y., Liu, X. (2015) Hypoglycemic effects of Zanthoxylum alkylamides by enhancing glucose metabolism and ameliorating pancreatic dysfunction in streptozotocin-induced diabetic rats. *Food Funct.* **6**, 3144-3154.
- Zhao, C., Yang, C., Liu, B., Lin, L., Sarker, S. D., Nahar, L., Yu, H., Cao, H., Xiao, J. (2018) Bioactive compounds from marine macroalgae and their hypoglycemic benefits. *Trends Food Sci. Technol.* **72**, 1-12.